

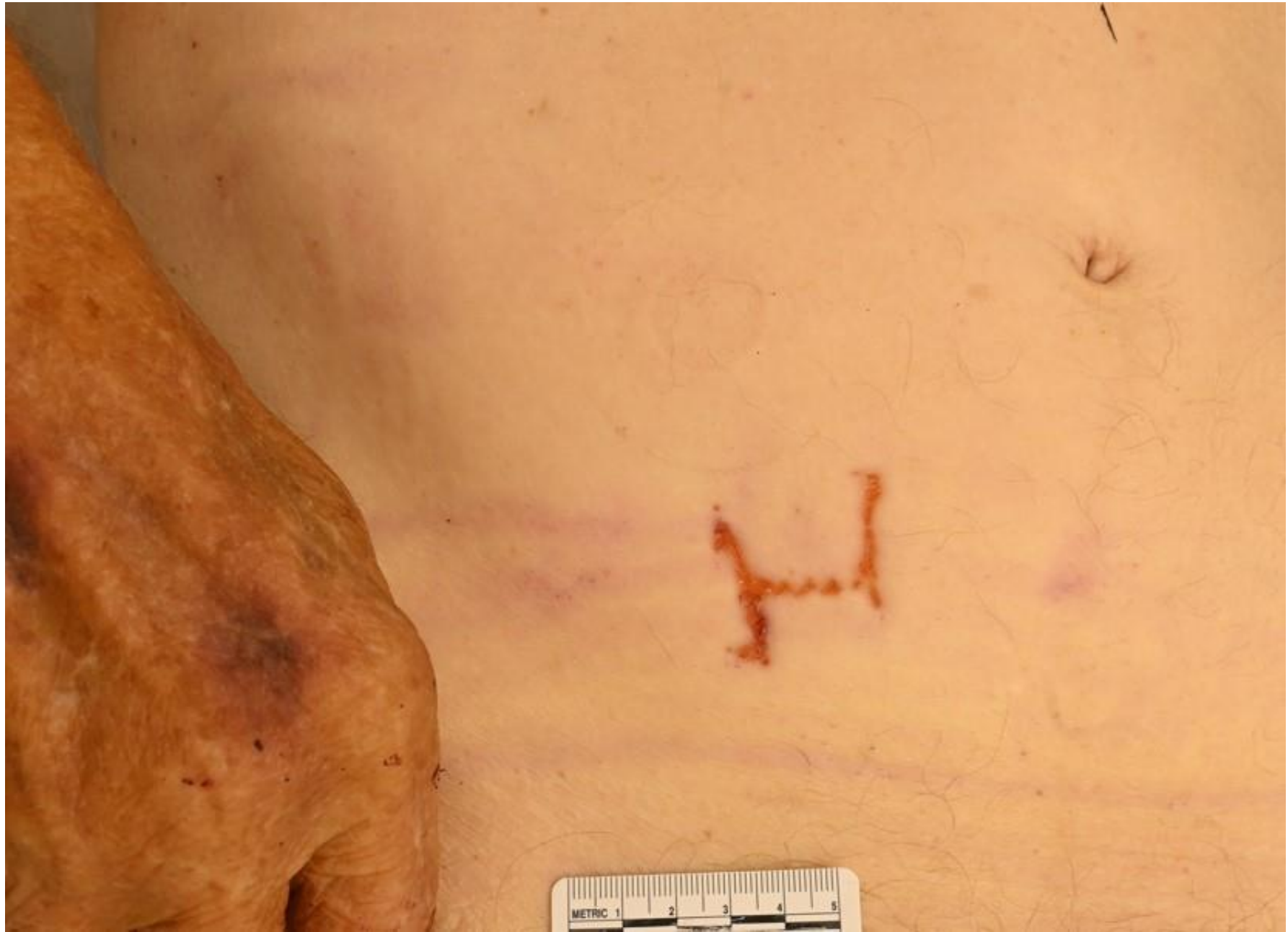

# Case #82

NAME Educational Activities Committee

Case provided by:

Dr. Andrew Layman, MD (Mayo Clinic, Rochester).



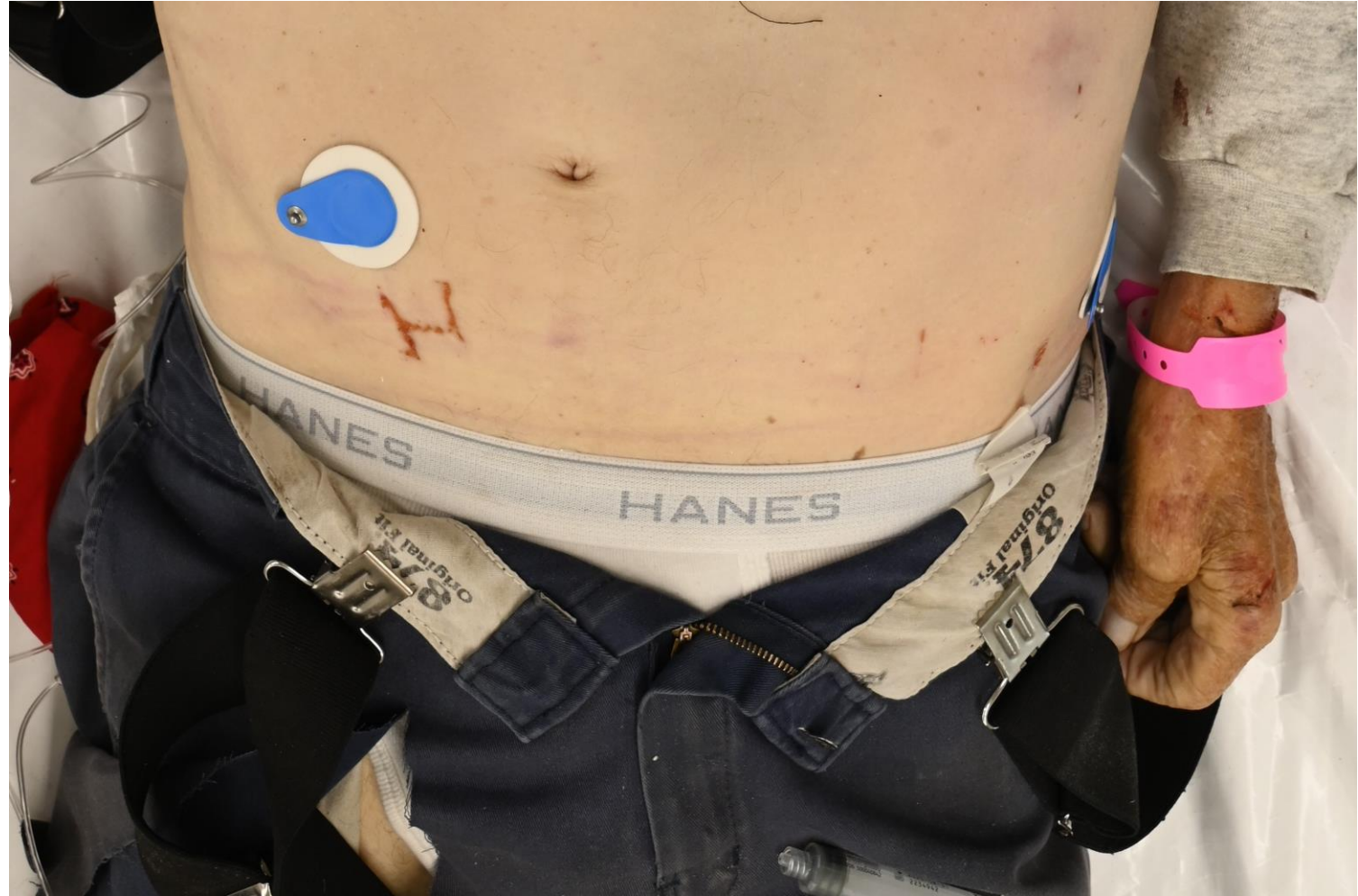1. An elderly man with a history of severe atherosclerotic cardiovascular disease and hypertension was involved in a head-on motor vehicle accident. EMS reported that airbags had deployed and the seatbelt had to be cut to remove the decedent from the vehicle. He was pronounced at the scene and the autopsy identified multiple blunt force injuries as the cause of death. During the autopsy, this dry yellow H-shaped injury was identified on the abdomen. What could have caused this injury? (Free text answer!)

Answer...

# Suspender clips!

The postmortem abrasion seen in the photo was consistent with the decedent's suspender clips that became entrapped between the decedent's abdomen and the seatbelt of the vehicle. The abrasion has a squared (H-shaped) configuration, and if you look closely you can see the suspender clip "teeth" marks.

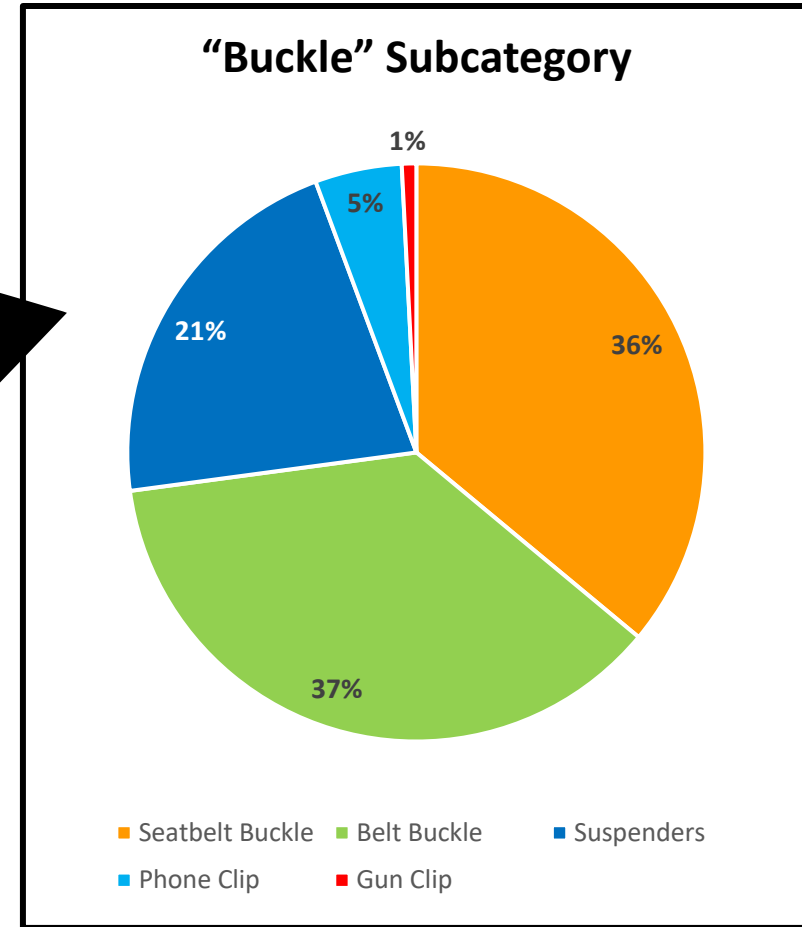
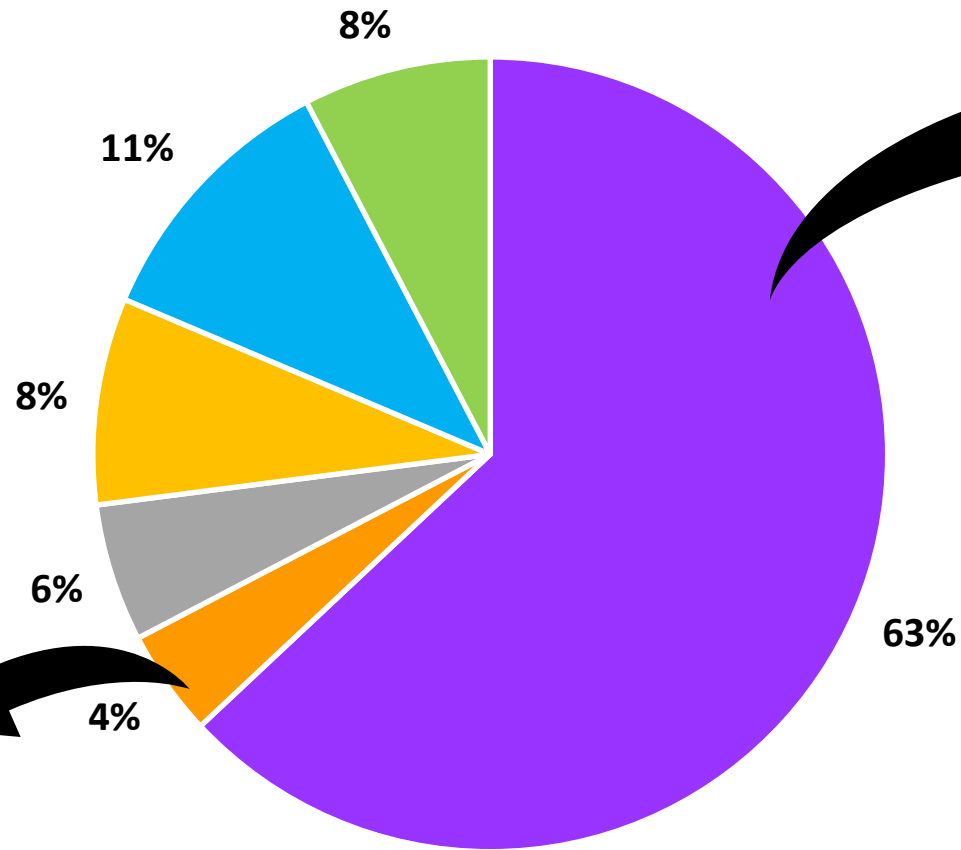
You can also observe the faint horizontal red linear across the abdomen consistent with the seatbelt, part of which crosses right over the patterned injury.



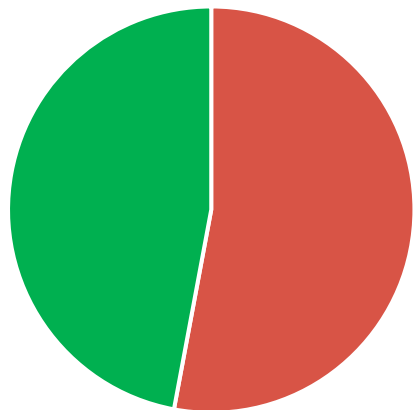
# Word Cloud

Postmortem injury Trauma shears cutting tool possibly  
airbag imprint abrasion cover injury phone  
seat steering wheel Suspender clip clasp  
imprint Seat belt Seat belt buckle Honda  
postmortem **Belt buckle** buckle perhaps  
artifact Ants Belt cutter  
Honda logo pants seatbelt carsuspenders Cell phone  
abrasion clip Seatbelt buckle holder  
clothing braces emblem mark looks Post mortem  
seatbelt cutter cut seatbelt Honda emblem

# Answers by Category



## "Postmortem Artifact" Subcategory



Ant activity Other

Buckle Postmortem Artifact  
Car Logo Imprint Extrication Injury  
Seatbelt Other



# Honorable mentions

- “This is where the space aliens put the probe in. Pretty classic really.”



- “Clip-on suspenders. Or a tiny tiny shark.”



- “Hebilla cinturón” → Apparently “Belt buckle” in Spanish!