

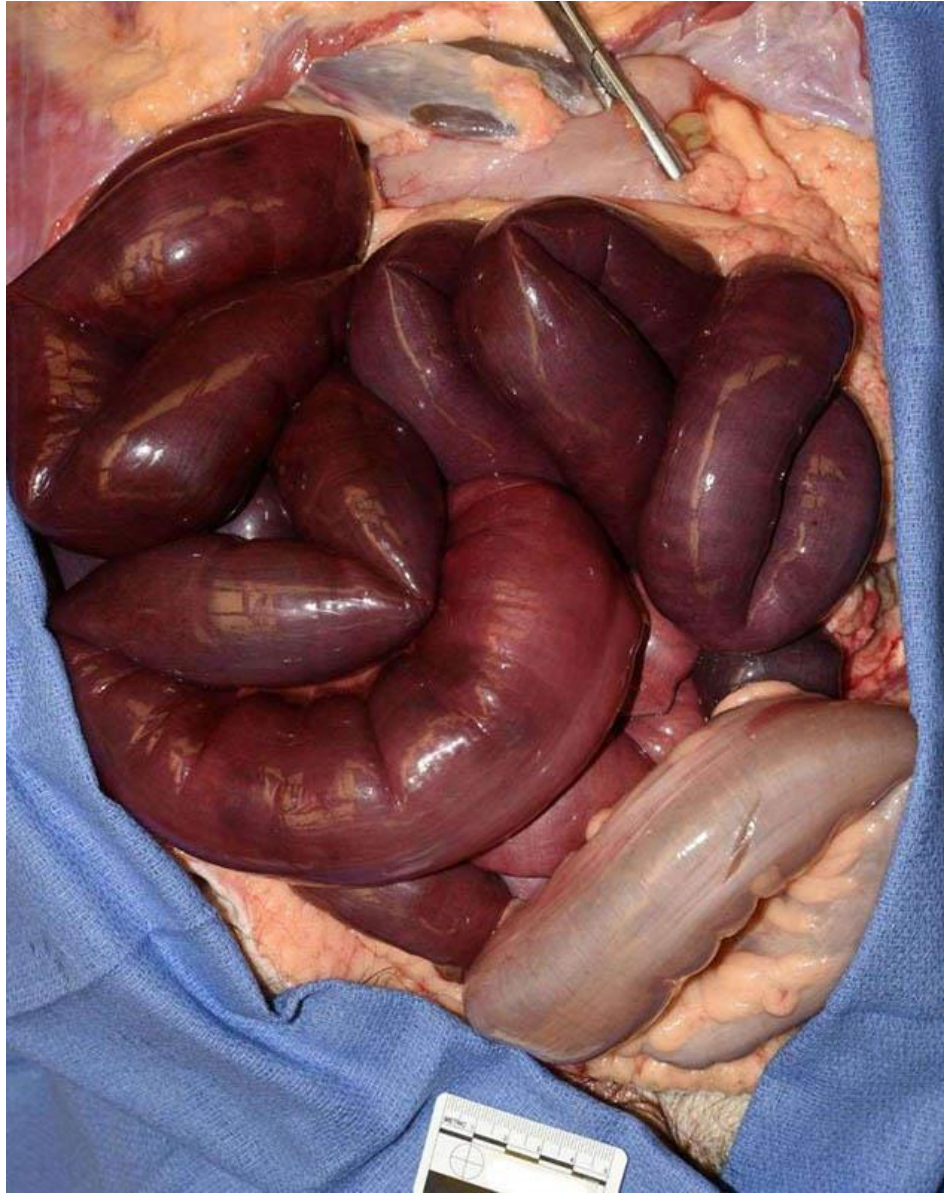Photo courtesy of Fabiola Righi, DO

1. The decedent is a nonverbal 41 year-old male with a past medical history of microcephaly, cerebral palsy with spasticity, and seizure disorder who was found unresponsive in his group home after reports of vomiting and fever. What is the most common association with this finding in adults?

- Coagulation disorder
- Cocaine use
- Congenital malformation
- History of abdominal surgery
- Adenocarcinoma of the sigmoid colon

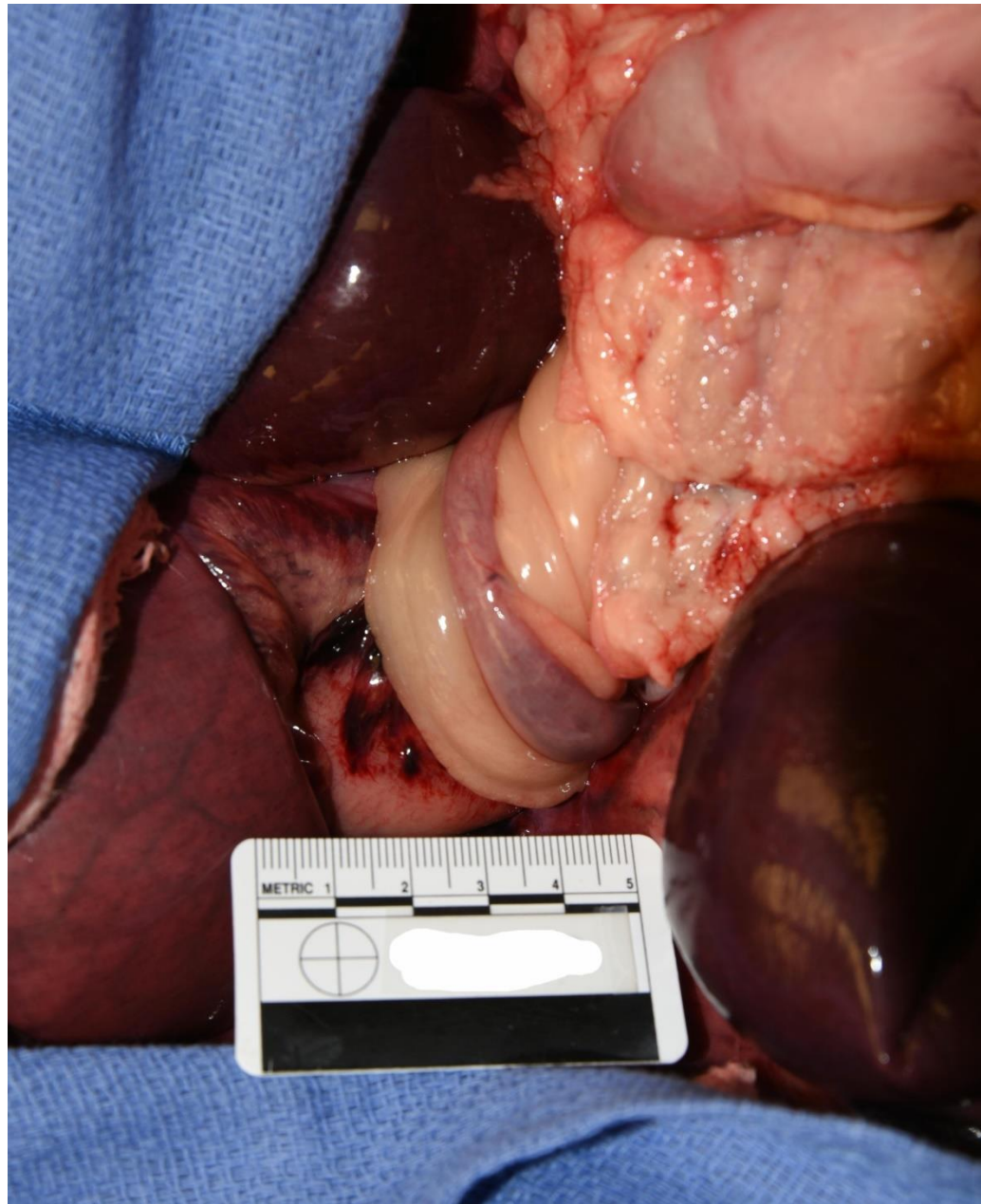


Photo courtesy of Fabiola Righi, DO



Thank you to everyone who responded to the case of the week. This case, submitted by Dr. Fabiola Righi, is a nice example of a cecal volvulus. The decedent was 41 years old, with cerebral palsy and seizure disorder. At autopsy, the bowel was dusky and dilated, consistent with an acute ischemic event. The point of torsion was identified (see attached photo) at the cecum, and showed patchy hemorrhage of the surrounding soft tissue. The twisted portion of bowel observed in the center of the attached image is the terminal ileum. This individual did not have a history of abdominal surgery, but volvulus in adults is most commonly related to postoperative adhesions.

Responses:

A. Coagulation disorder (9.95% responses)

Clotting abnormalities, such as Factor V Leiden, can be risk factors for ischemic bowel disease, but these cases are not particularly common, and do not have an association with intestinal volvulus.

B. Cocaine use (0.45% responses)

Although cocaine is a well-known central nervous system stimulant associated with vasospasms and vasoconstriction, and has been previously described as a cause of ischemic bowel disease, these cases are generally considered rare complications, and do not have an association with intestinal volvulus.

C. Congenital malformation (24.89% responses)

In children, volvulus is most commonly associated with congenital malformations, especially intestinal malrotation. In this disorder the narrow mesenteric base permits abnormal mobility of the small bowel, allowing the mesentery to twist. Approximately one-third of children with malrotation present with the life-threatening complication of volvulus before one month of age, with approximately 90% of patients with malrotation being diagnosed within the first year of life.

D. History of abdominal surgery (Correct Answer, 62.44% responses)

Volvulus is a well-recognized cause of acute intestinal obstruction, occurring most often in the sigmoid colon and cecum, with volvulus of the small bowel rarely being encountered in the adult population of the United States. Volvulus can be primary, without any predisposing anatomic abnormalities or risk factors, or secondary to congenital or acquired lesions. Postoperative adhesions are the most common cause of secondary volvulus in adults. The volvulus rotation (torsion) causes vascular insufficiency, resulting in ischemia and tissue hypoxia. Substantial increases in intraluminal pressure and dilation of the bowel segment further compromise vascular supply to the intestinal wall, ultimately leading to hemorrhagic infarction and perforation, which is associated with high morbidity and mortality. CT scans may reveal torsion of loops of small bowel around the mesenteric vessels and mesentery known as the “whirl sign”. Other radiographic signs, such as the “spoke wheel,” “beak,” and “barber pole” signs, have been described in the literature as well. Of note, although this pathology represents a rare cause of small bowel obstruction in Western countries, in Asia and Africa, it can represent between 20 and 50% of the cases. Possible related factors have been proposed such as uptake of large quantities of fiber after prolonged fasting, as occurs with Muslims during The Ramadan festival.

E. Adenocarcinoma of the sigmoid colon (2.26% responses)

Colon cancer is one of the most common causes of intestinal obstruction, accounting for approximately 60% of cases. Although the burden of tumor can cause elongation and dilation within the sigmoid colon, becoming a leading source of volvulus torsion, this etiology is a less prevalent source of volvulus than the ones previously mentioned, only resulting in colonic volvulus 5% of the time.

**Resources:**

<https://pubmed.ncbi.nlm.nih.gov/11005354/>

<https://www.sciencedirect.com/science/article/pii/S2210261215004575>

<https://www.hindawi.com/journals/crim/2015/391093/>

<https://www.sciencedirect.com/science/article/pii/S1072751507019278#bbib1>

<https://journals.sagepub.com/doi/pdf/10.1177/000313480907501206>