



Case #34

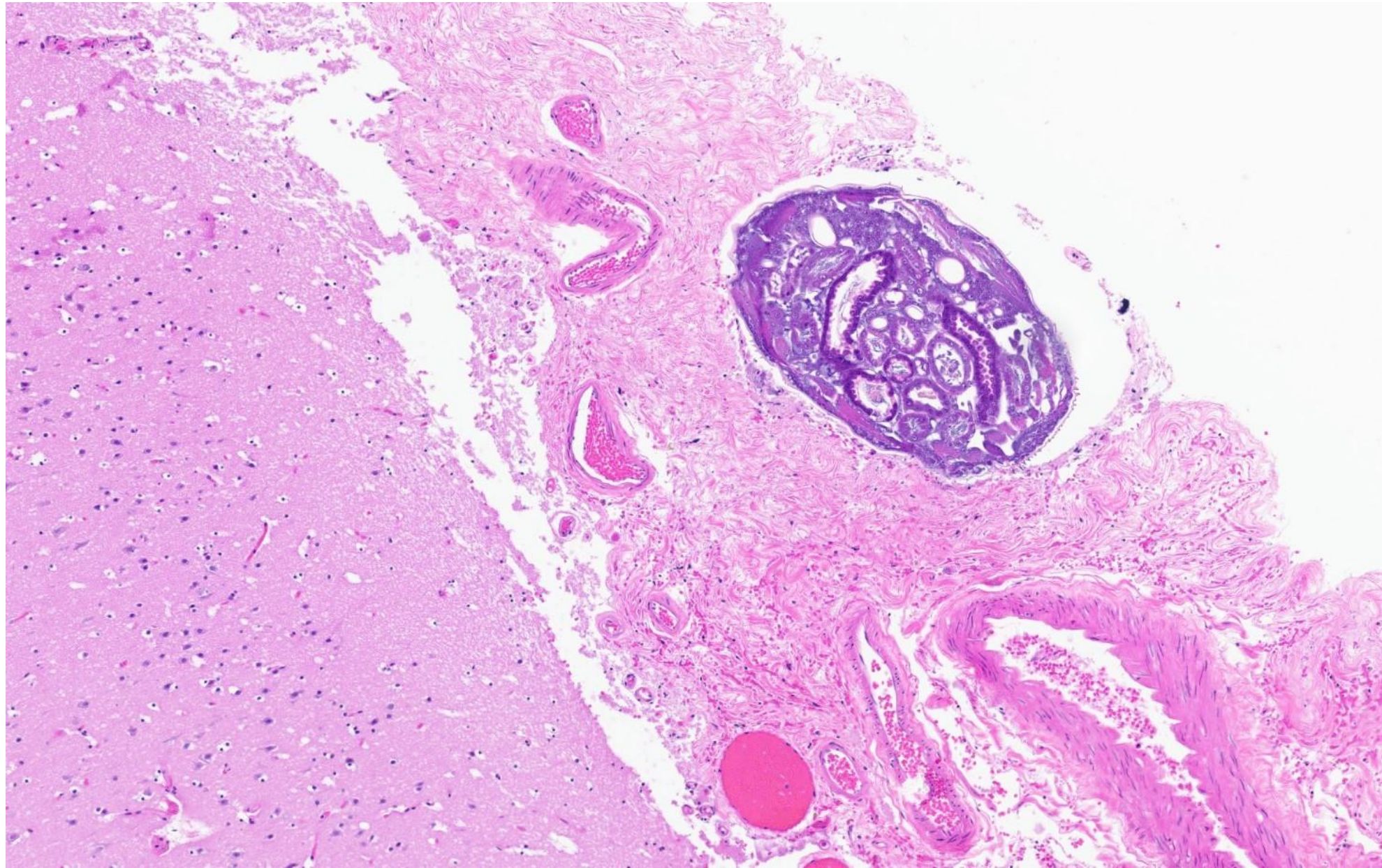
NAME Educational Activities Committee

Case provided by:

Dr. Ryan Kendziora (PGY3)

Dr. Catherine Hagen (Senior Associate Consultant)

Mayo Clinic, Rochester.



1. The decedent was a 26-year-old male found dead in the woods with a gunshot wound of the head.

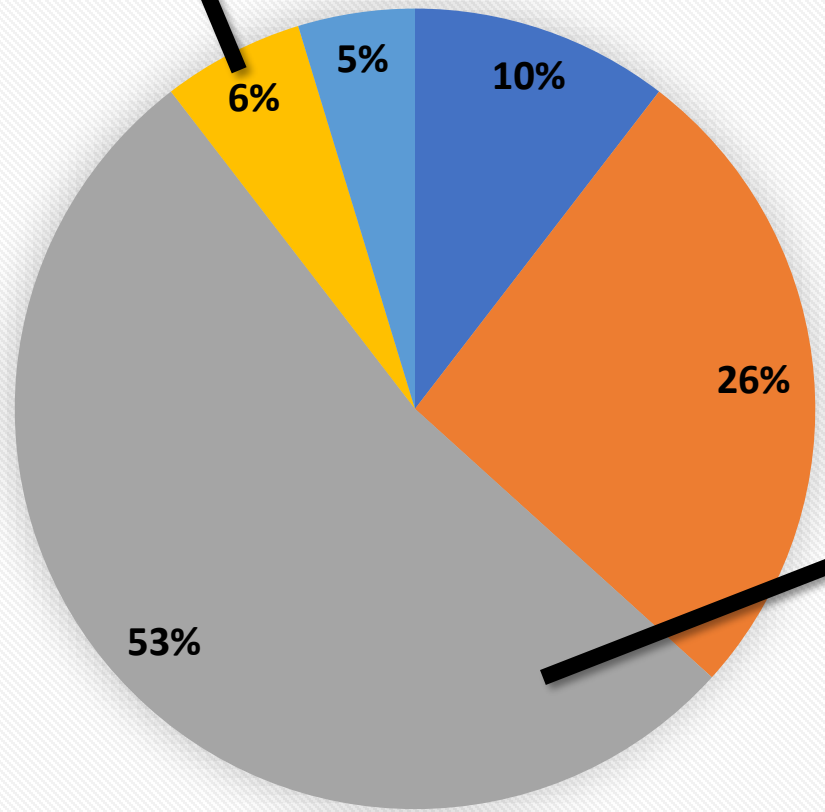
What is the incidental finding noted on brain histology? (FREE TEXT ANSWER)

Word Cloud

Metastatic tumor Schistosomiasis artifact infection Cross section
Parasitic brain Neurocystocercosis larvae nematode
Neurocysticercosis Parasitic worm parasite
Taenia solium Maggot eggs Cysticercosis tumor
worm Bug Metastatic adenocarcinoma sort
fly larva postmortem insect larva infestation tissue insect

From either carryover during dissection of directly by the projectile

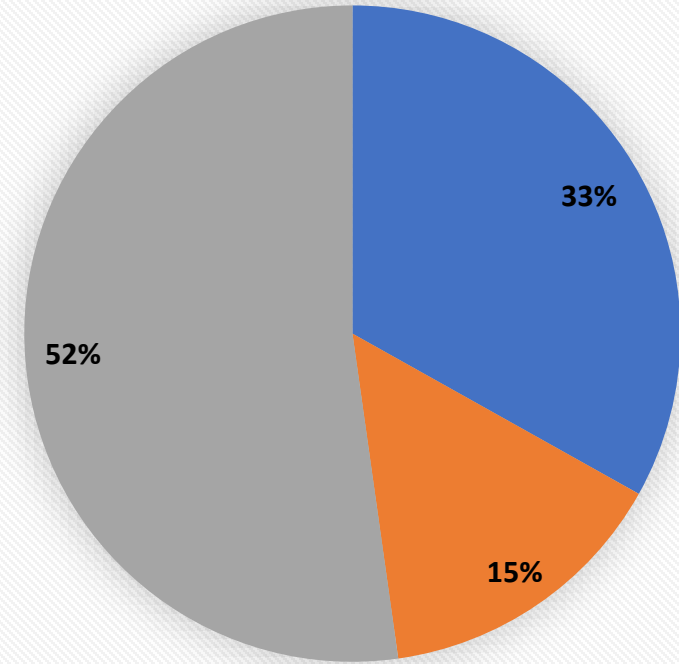
Answer Choice by Category



■ Tumor ■ Maggot ■ Parasite ■ Ectopic tissue ■ Other



Parasite-related answers



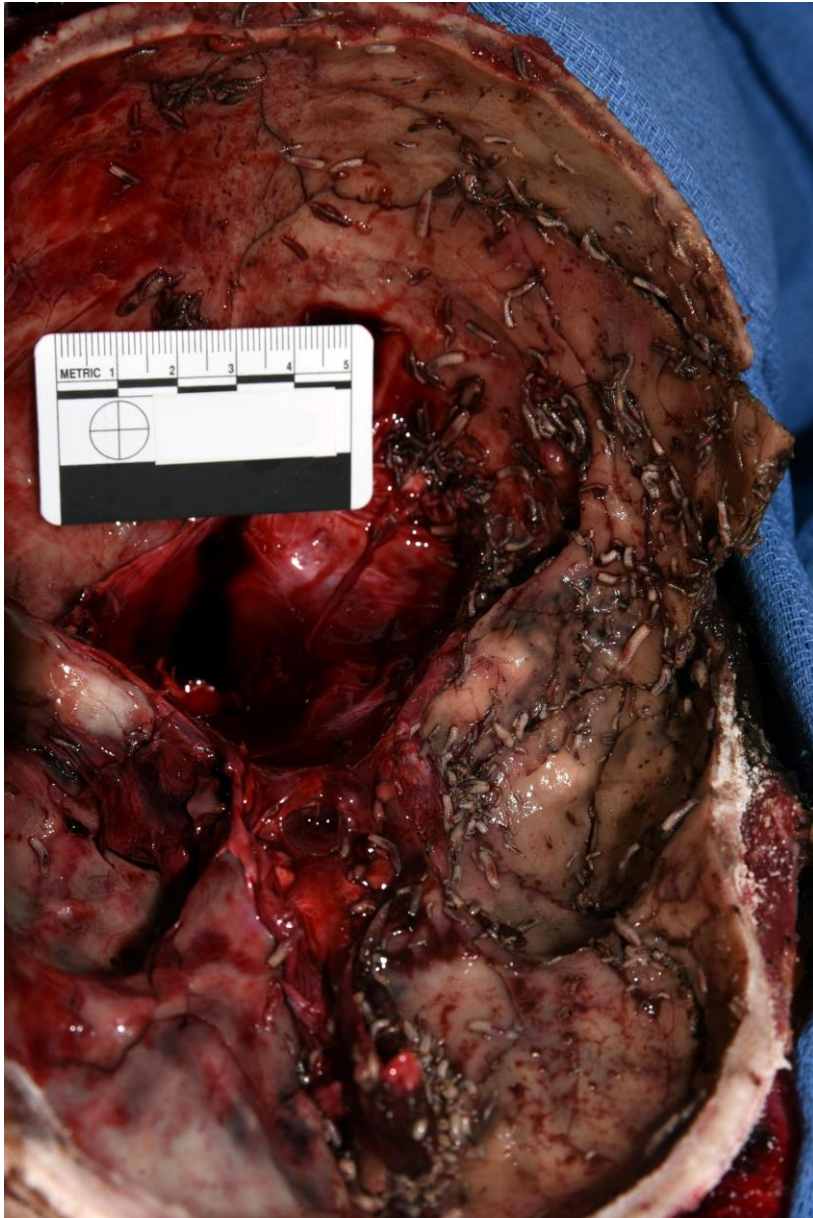■ Parasite NOS ■ Other Parasite ■ Neurocysticercosis

Answer...

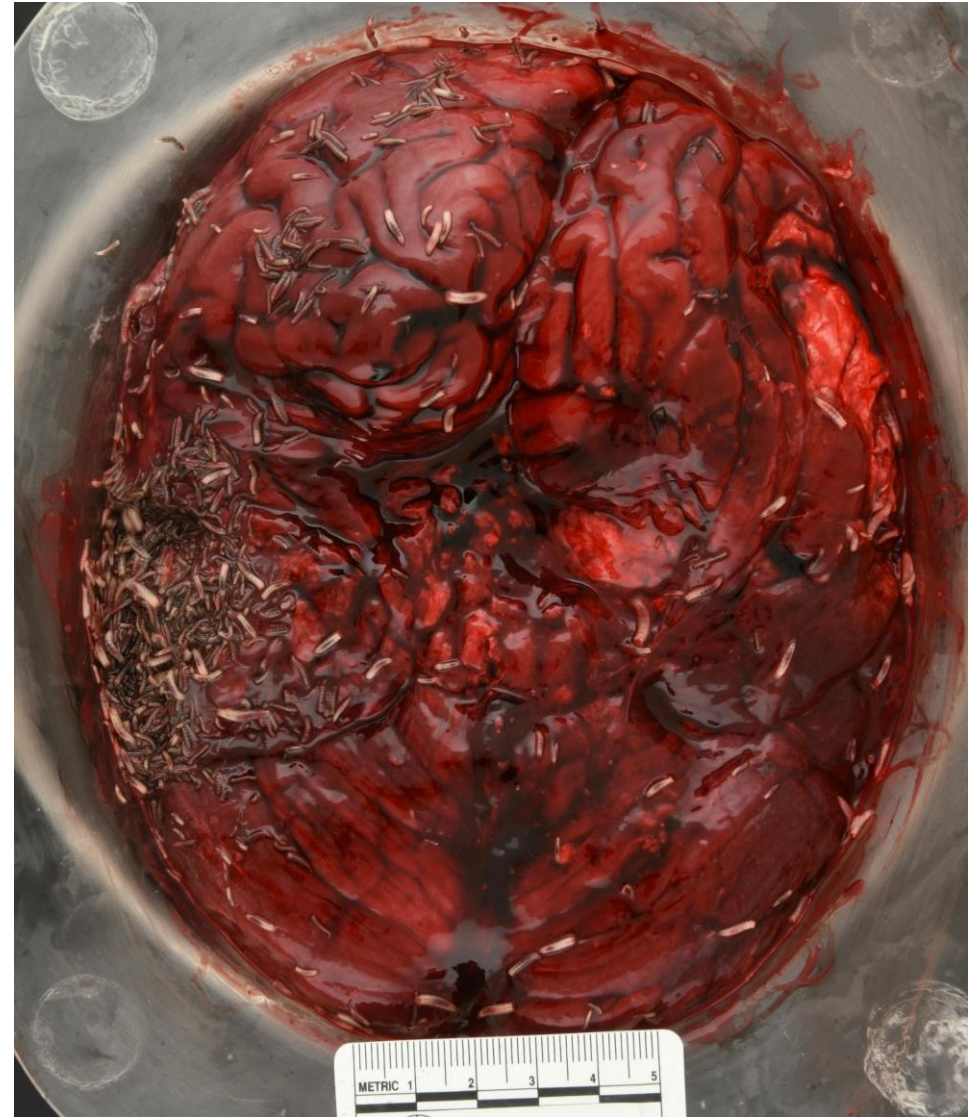Maggot!

The decedent is a 26-year-old male who was found dead in the woods with a gunshot wound of the head. Prior to his discovery, he had been missing for almost three days. At autopsy, he was in a moderate state of decomposition with skin marbling, slippage, and discoloration, as well as extensive maggot activity. Large numbers of maggots were present within the cranium and atop the brain, having entered through the skull defect made by the bullet. This individual maggot, resting within a leptomenigeal vessel prior to autopsy, incidentally made its way into the cassette taken for routine examination of the brain. Note the lack of tissue reaction or cyst formation, which distinguishes this postmortem finding from an antemortem parasitic infection.

Maggot activity typically becomes evident approximately 2 days postmortem and can become extensive 4-10 days after death, though the timing depends on local environmental factors (1). The approximate timeline matches that of the decedent in this case, given that he was missing for three days and found outdoors. Maggots can have several forensic uses: for example, forensic entomologists can more precisely estimate time of death by measuring the size of the oldest larvae present. In addition, substances present in tissue being consumed by maggots can be detected by a toxicology lab in the maggots themselves, which can serve as a helpful alternative to blood toxicology in cases with severe decomposition (2).



Base of Skull



Brain

Neurocysticercosis was another common answer we received, which is caused by parasitic infection of the central nervous system with larval stages of *Taenia solium*. These immature worms can penetrate the intestinal mucosa and reach several organs via the bloodstream. Inflammation, gliosis, fibrosis and necrosis can be identified in the surrounding tissue depending on the stage of infection. As you can see in our case, there is no surrounding tissue reaction to the parasite. Histology will show a parasite with calcareous corpuscles (irregularly shaped membranous foldings, 1) and scolices (hooklets, 2), generally surrounded by translucent fluid that is lined by a thin membranous wall.

Neurocysticercosis showing *T. Solium* with hooklets and calcareous corpuscles

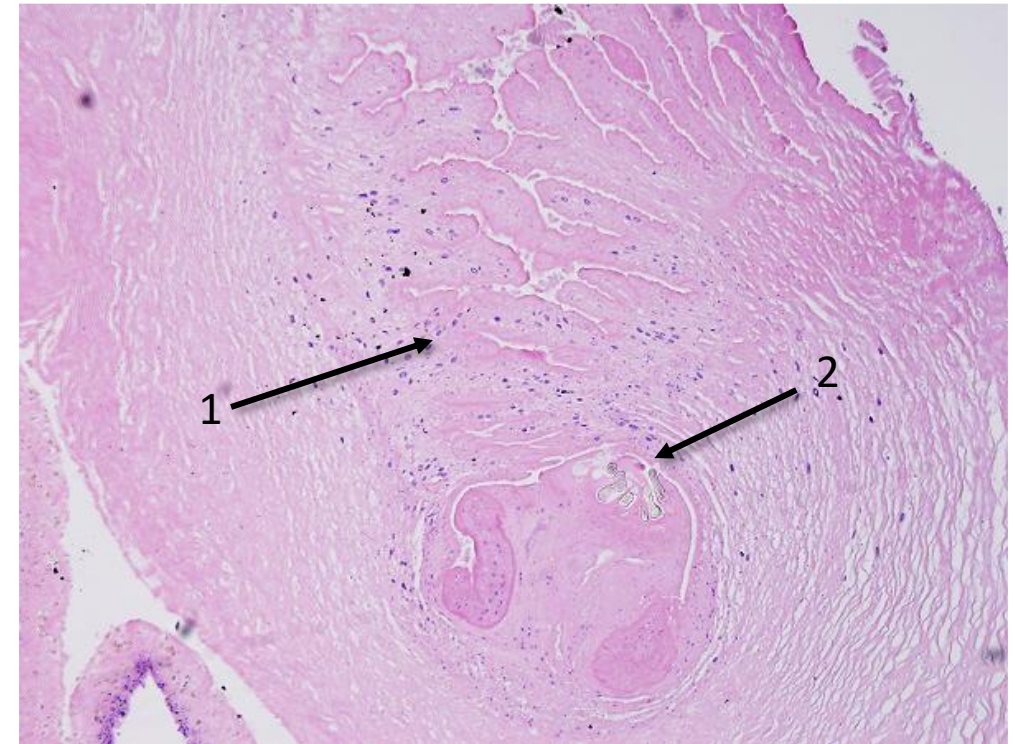


Image courtesy of Dr. Audrey Schuetz, Mayo Clinic Rochester

Reference:

- Shrestha et al. Methods Of Estimation Of Time Since Death. [Updated 2021 Jul 20]. In: StatPearls [Internet]. Treasure Island (FL): StatPearls Publishing; 2021 Jan-. Available from: <https://www.ncbi.nlm.nih.gov/books/NBK549867/>
- Joseph et al. The use of insects in forensic investigations: An overview on the scope of forensic entomology. J Forensic Dent Sci. 2011;3(2):89-91. doi:10.4103/0975-1475.92154