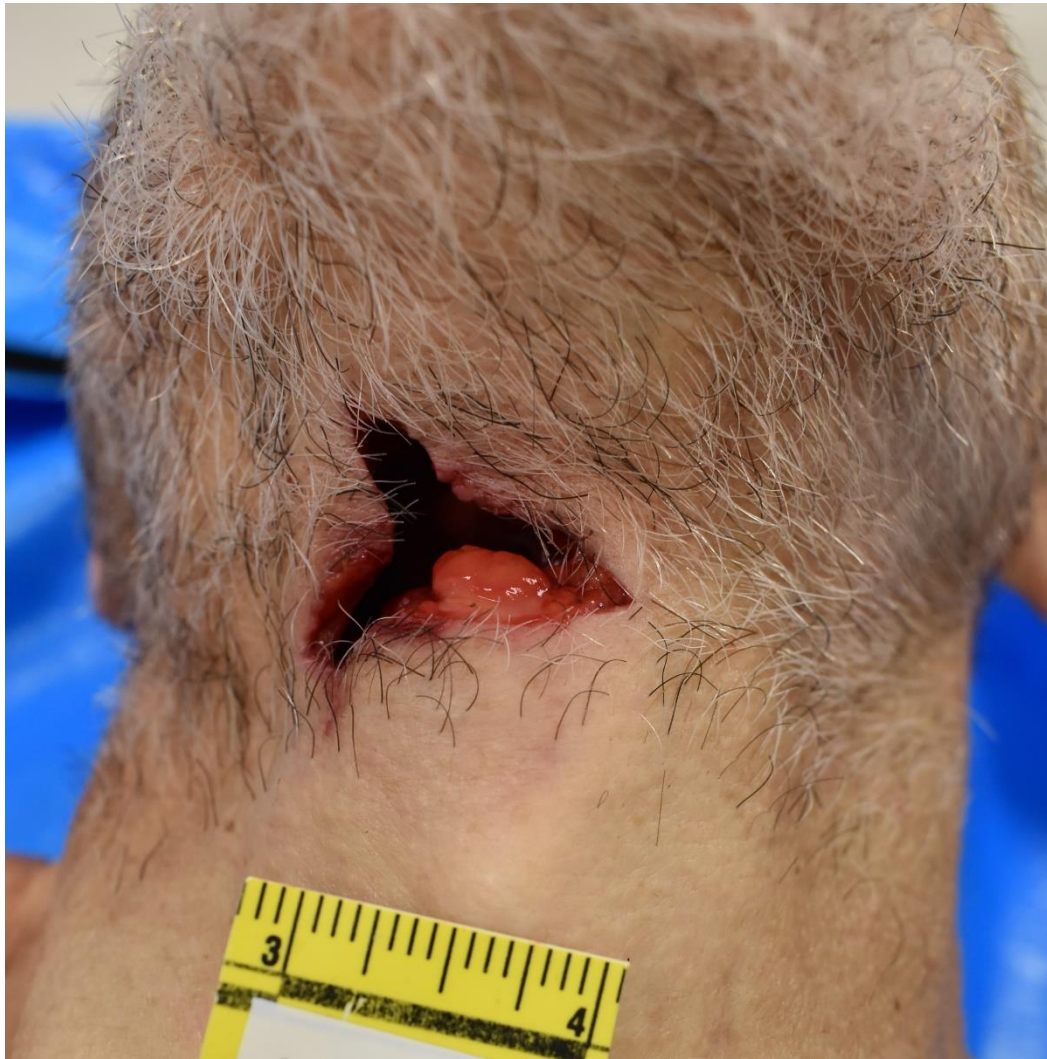

An elderly male is found dead at home with an injury under the chin. The most likely cause of this injury is:

- A. Contact gunshot wound, handgun
- B. Fall from ladder onto fence post
- C. Crossbow injury
- D. Stab wound (knife)
- E. Nail gun injury



Case courtesy of Theodore (Ted) Brown, MD (Homer Stryker M.D. School of Medicine, Western Michigan University)

A. Contact gunshot wound, handgun (12.63% responses)

Contact entrance wounds in this area of the body often appear as a circular or ovoid loss of tissue and have an abrasion margin. In addition, contact gunshot wounds can be associated with a muzzle imprint, searing, and soot deposition.

B. Fall from ladder onto fence post (29.21% responses)

A fall from a ladder onto a fence post may result in an impalement-type injury as a rigid blunt object penetrating the body. In impaling wounds, the features of penetrating trauma are combined with those of blunt force tissue damage. A blunt object like a fence post must first penetrate the skin, which would likely result in features that include a laceration with rough, abraded or contused, wound edges and strands of tissue bridging the tear of the skin.

C. Crossbow injury ([Correct answer, 48.68% responses](#))

A crossbow bolt with a 3-blade broadhead caused the entrance wound in this case. The wound highlights the tripolar nature of a crossbow defect. The two most common types of crossbow heads are field points and broadheads. In general, wounds caused by broadhead crossbow bolts produce a very characteristic pattern that corresponds to its geometry, generally a 2- or 3-pointed star. The vanes will produce incisions that generally lack abraded edges. A field point head can produce a circular, oval, or slit-like wound pattern. In addition to the patterned wound in this case, the cause of the wound was straightforward at autopsy because a large segment of the crossbow bolt remained in the decedent's head (see additional image).

D. Stab wound (knife) (6.58% responses)

Knives generally cause incised or stab wounds. The appearance of the wound varies based on the features of the knife used, which includes sharpness, edge type (smooth/serrated), number of cutting edges, and how deep the knife penetrated. Irregular sharp wounds can result from a knife wound for many reasons, which may include movement of the knife or body while the knife penetrated the body or successive stabs in the same area of the body. The patterned, tripolar wound in this case makes a knife stab wound less likely.

E. Nail gun injury (2.89% responses)

Pneumatic and electric nail guns are low-velocity tools and typically cause circular puncture entrance wounds. Nail gun injuries are often compared with conventional firearms because most nail guns can fire a nail at a velocity ranging from 46 to 150 m/s, whereas conventional handguns and rifles generate velocities from 91 to 671m/s.

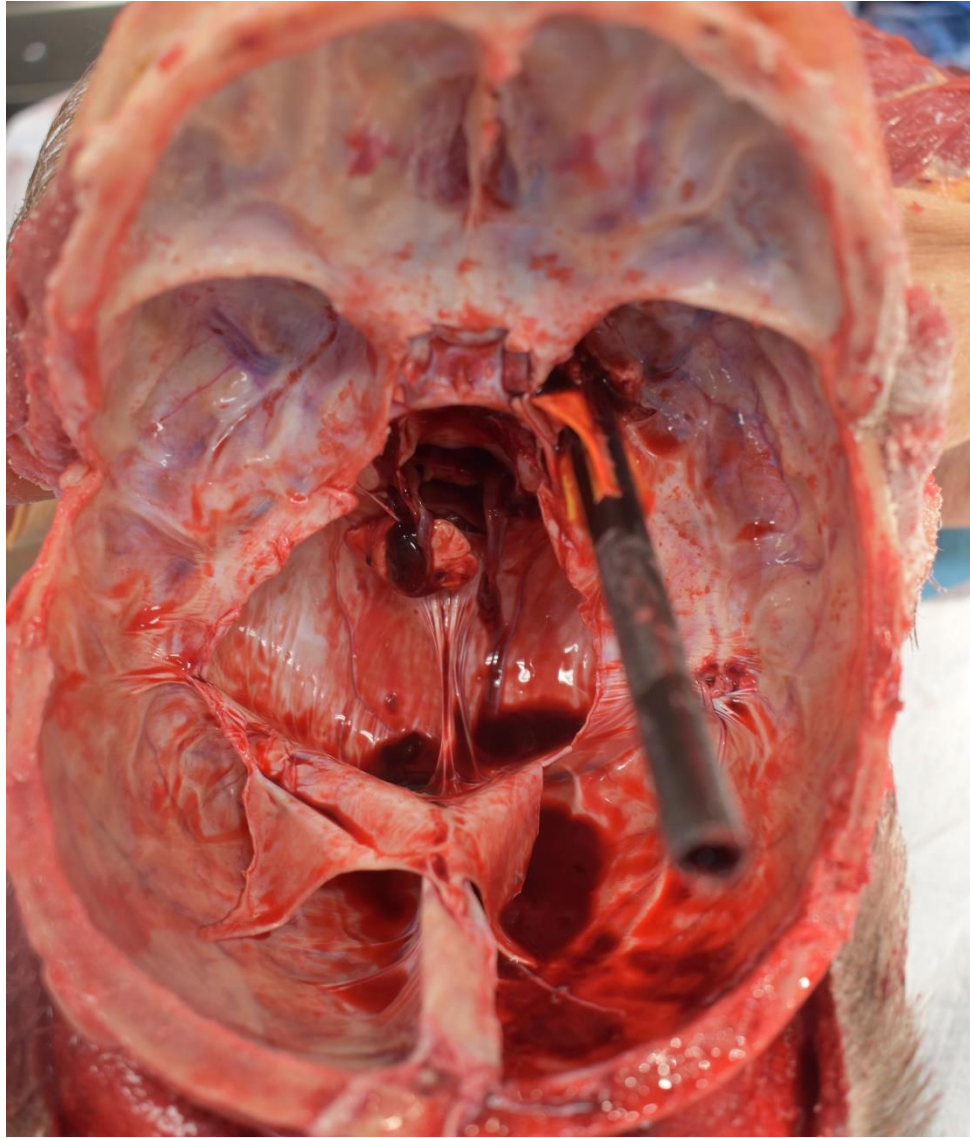




Image from https://www.sportsmans.com/hunting-gear-supplies/archery-gear-equipment-supplies/points-broadheads/fixed-blade-broadheads/g5-striker-100-gr-crossbow-broadhead-3-pack/p/1640435?channel=shopping&gclid=CjwKCAjw07qDBhBxEiwA6pPbHq1DhRt3OAIzYtepNXU0Lk3ilgJc mWzzxAQ9w--7aOQZ79cVdDNQzRoC270QAvD_BwE

References:

Shrestha R, Kanchan T, Krishan K. Gunshot Wounds Forensic Pathology,; 2021. <http://www.ncbi.nlm.nih.gov/pubmed/32310579>.

Franceschetto L, Carlini L, Lancia M, et al. An unusual case of homicide by impalement with a battering ram. Am J Forensic Med Pathol. 2019;40(2):150-152. doi:10.1097/PAF.0000000000000476

Hlavaty L, Sung L. Horticultural Homicide: Stab Wound to the Chest Masquerading as Impalement by Rose Bush. Am J Forensic Med Pathol. 2018;39(4):341-344. doi:10.1097/PAF.0000000000000428

Tamburro L, Brown T, Bauler LD. A Case of Crossbow Homicide With Review of Crossbow Injuries and Manner of Death Considerations. Am J Forensic Med Pathol. 2020;41(4):315-320. doi:10.1097/PAF.0000000000000564

Jacques R, Kogon S, Shkrum M. An experimental model of tool mark striations by a serrated blade in human soft tissues. Am J Forensic Med Pathol. 2014;35(1):59-61. doi:10.1097/PAF.0000000000000078

Harle L. Sharp force injuries. PathologyOutlines.com website. <https://www.pathologyoutlines.com/topic/autopsysharpforce.html>. Accessed April 8th, 2021.

Fernando DMG, Ekanayake EMKB. Nail Gun Suicide. Am J Forensic Med Pathol. 2020;Publish Ah(00):1-8. doi:10.1097/paf.0000000000000650