

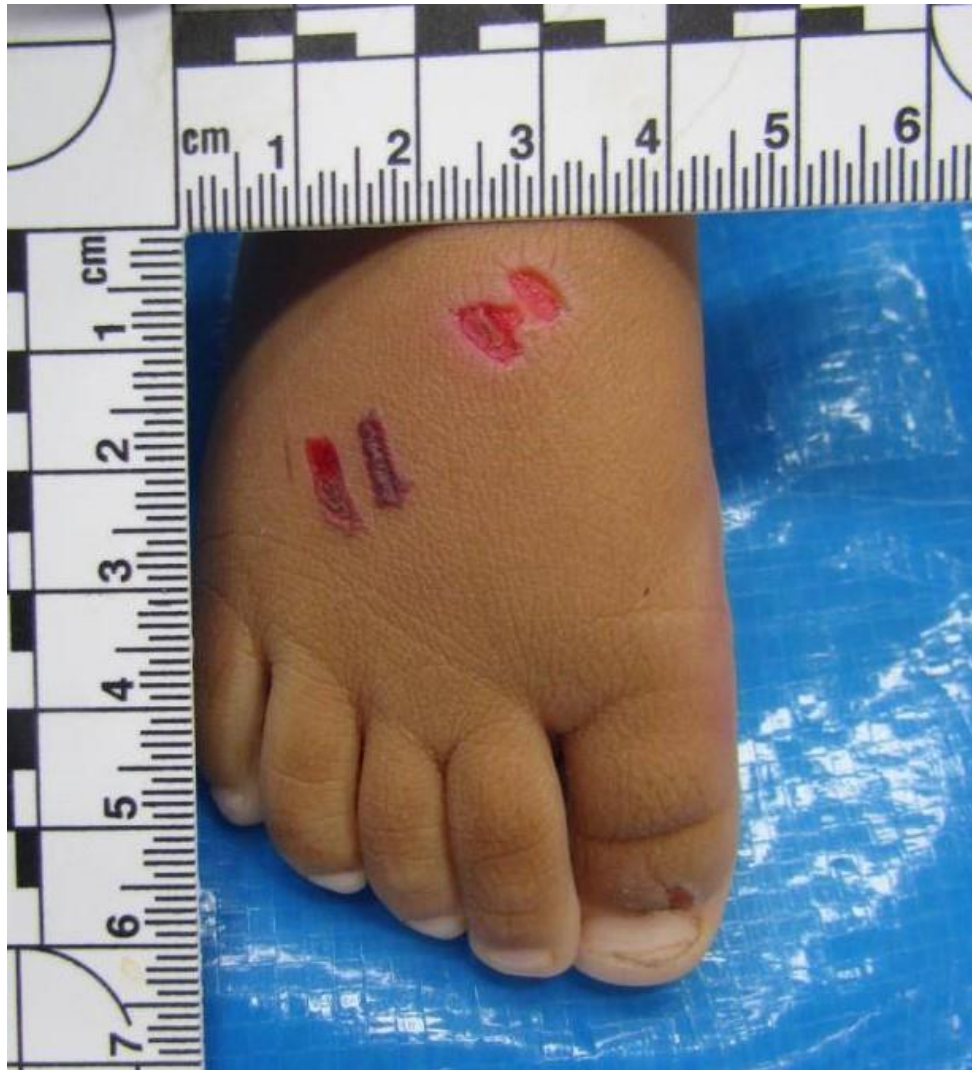

Photo courtesy of the Southwestern Institute of Forensic Sciences , Dallas TX

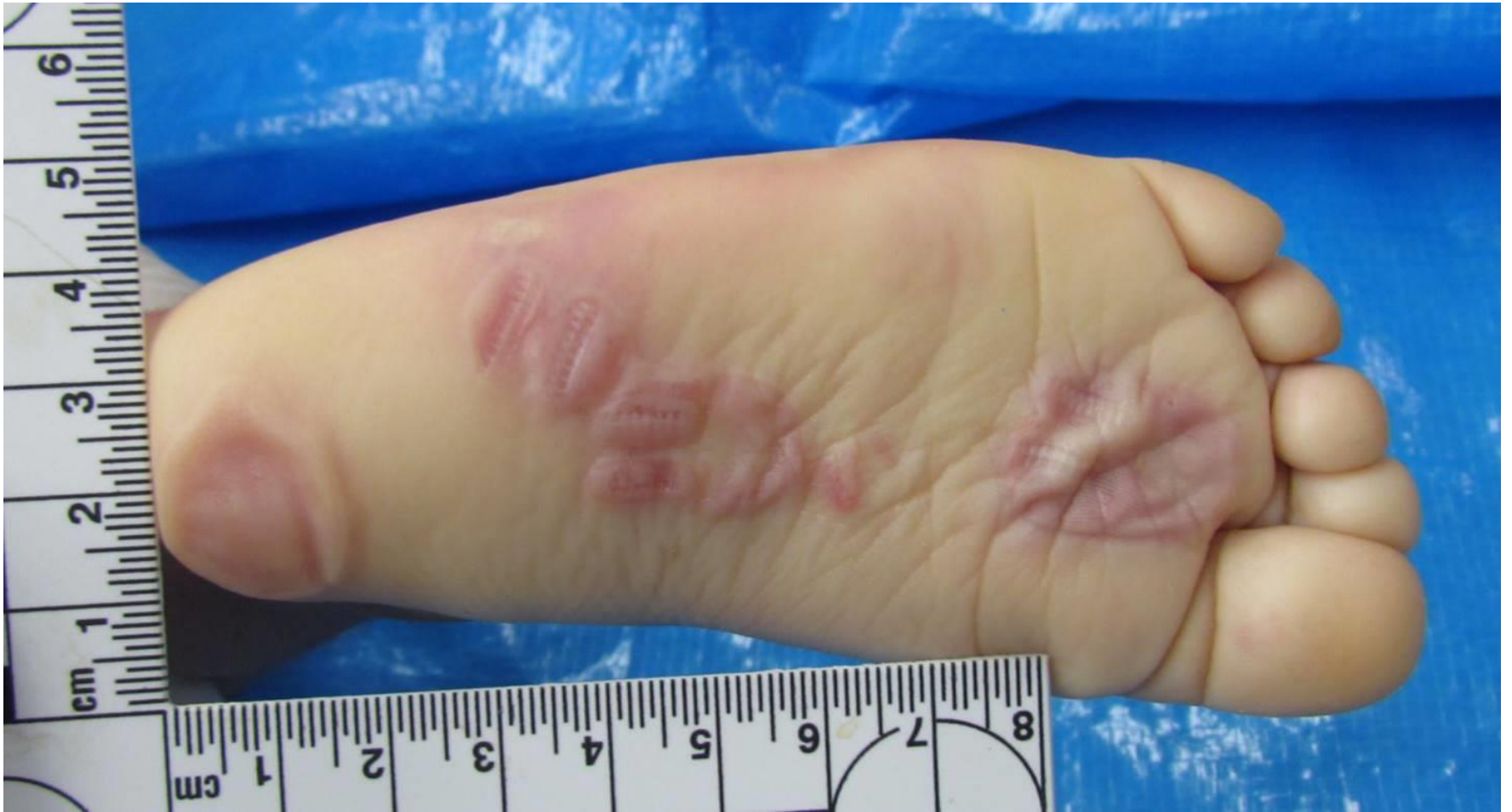

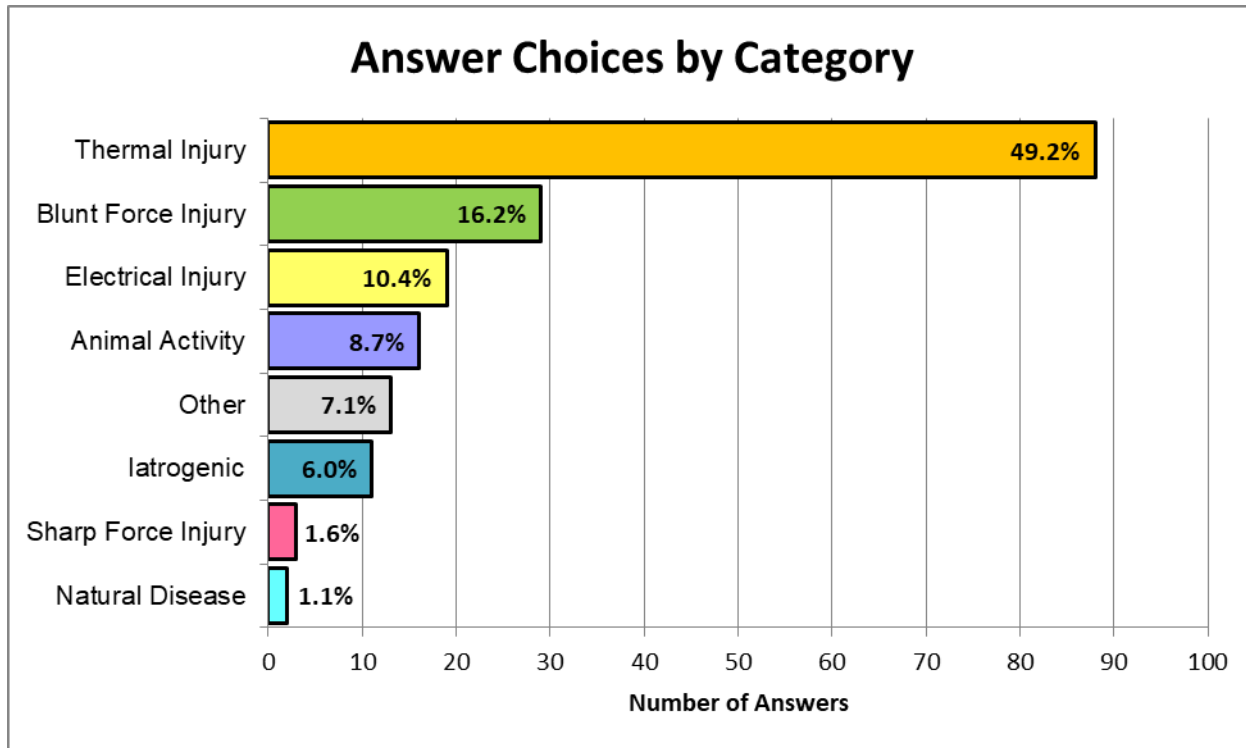
Photo courtesy of the Southwestern Institute of Forensic Sciences , Dallas TX

Q1 The decedent is a 6 month-old boy found unresponsive in bed. Identify the lesions observed on the foot (free-text answer):

foot disposable cigarette lighter electrical burns snake bites one two prongs Bite forceps  
Cigarette lighter burns two top Contact healing Rat bite pliers blisters  
thermal injury sort lighter Burns disposable  
patterned cigarette lighter burns electrical injury clip  
marks impressions heated hot lighter lesions electric look idea  
patterned injury wounds clamp animal activity abrasions top foot  
lighter burns zipper

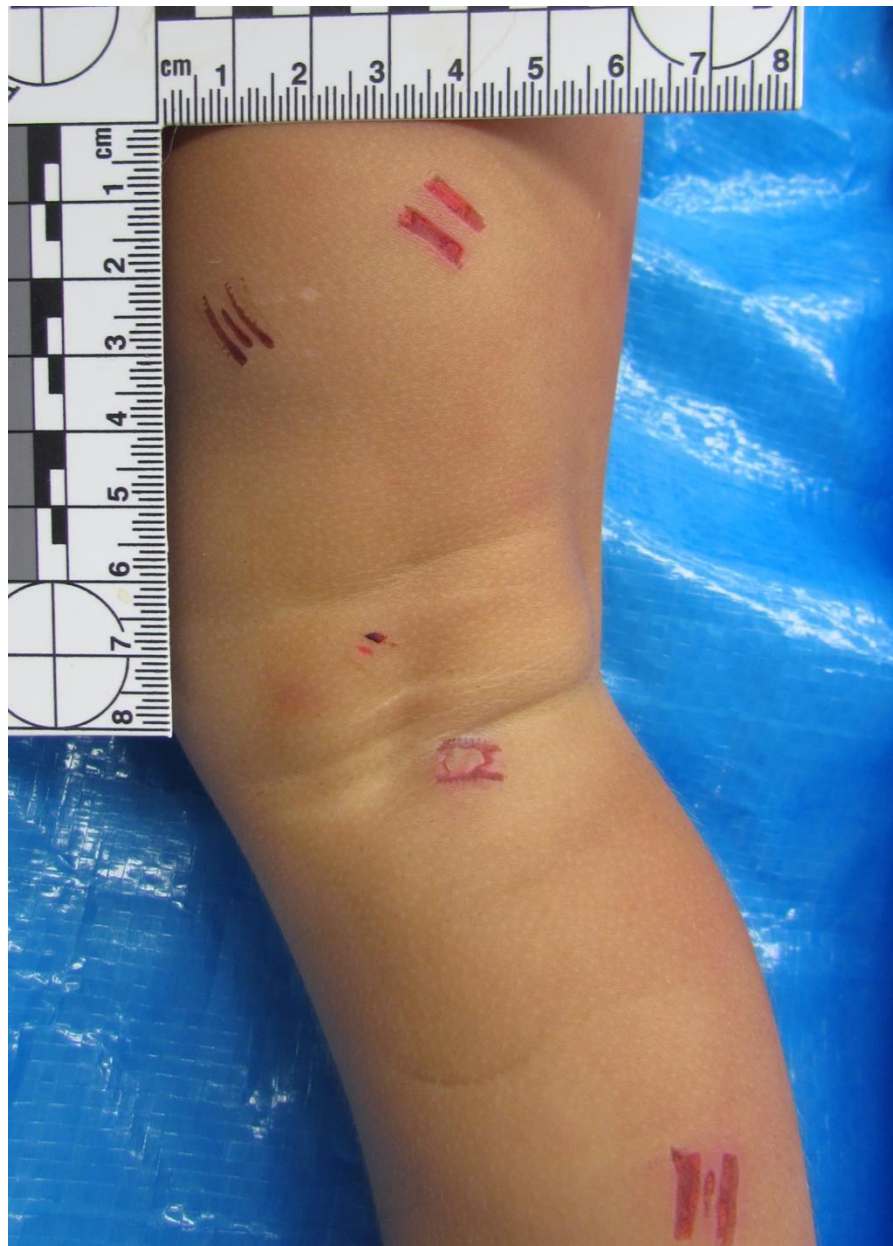(Word cloud generated from 184 responses)

## Answer Choices by Category

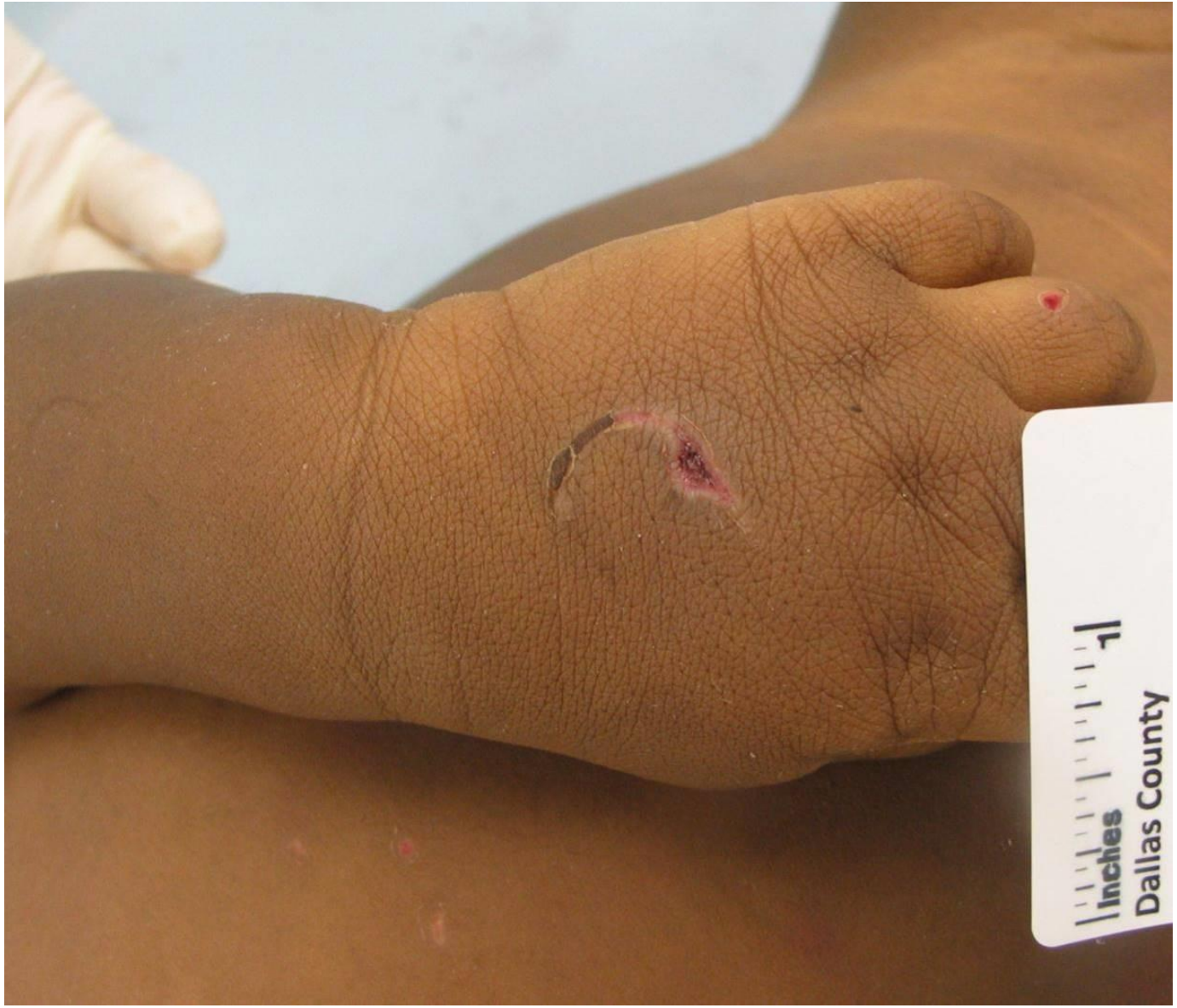



Correct answer: cigarette lighter burns



Additional injuries from the same case



Healing burn from a different case