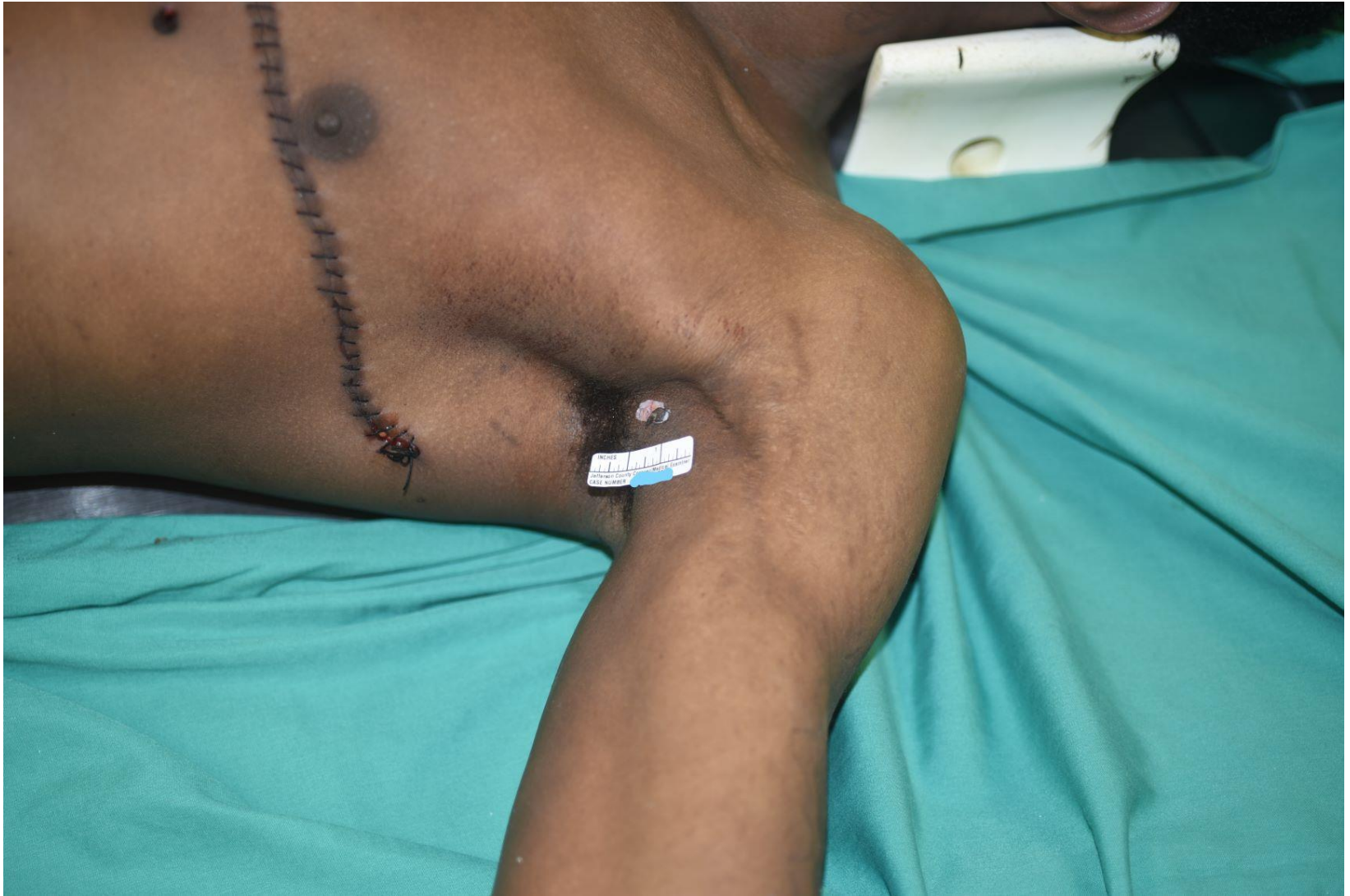


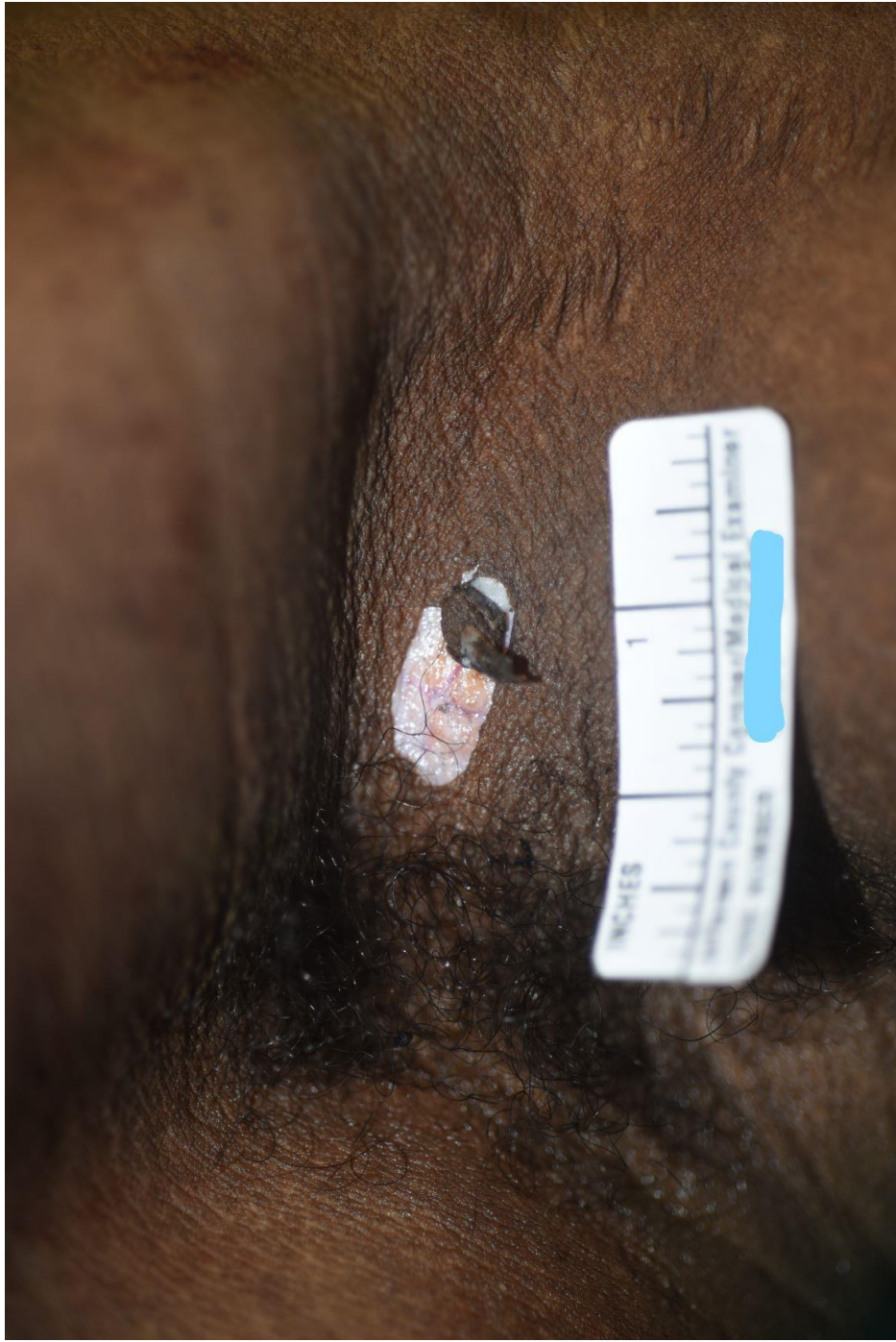
Case #26

NAME Educational Activities Committee



Case and images courtesy of Dr. Cori Clark (PGY3) and Dr. Daniel Dye (FP Fellowship Program Director, University of Alabama at Birmingham)



The decedent is a 21-year-old man who was transported to a local hospital after being injured in an altercation. He arrived by private vehicle and was immediately taken to surgery by the Trauma Team. Despite medical intervention, he died in the operating theater. During the postmortem examination, an injury was identified in the decedent's axilla.

What caused the injury depicted in the photographs?

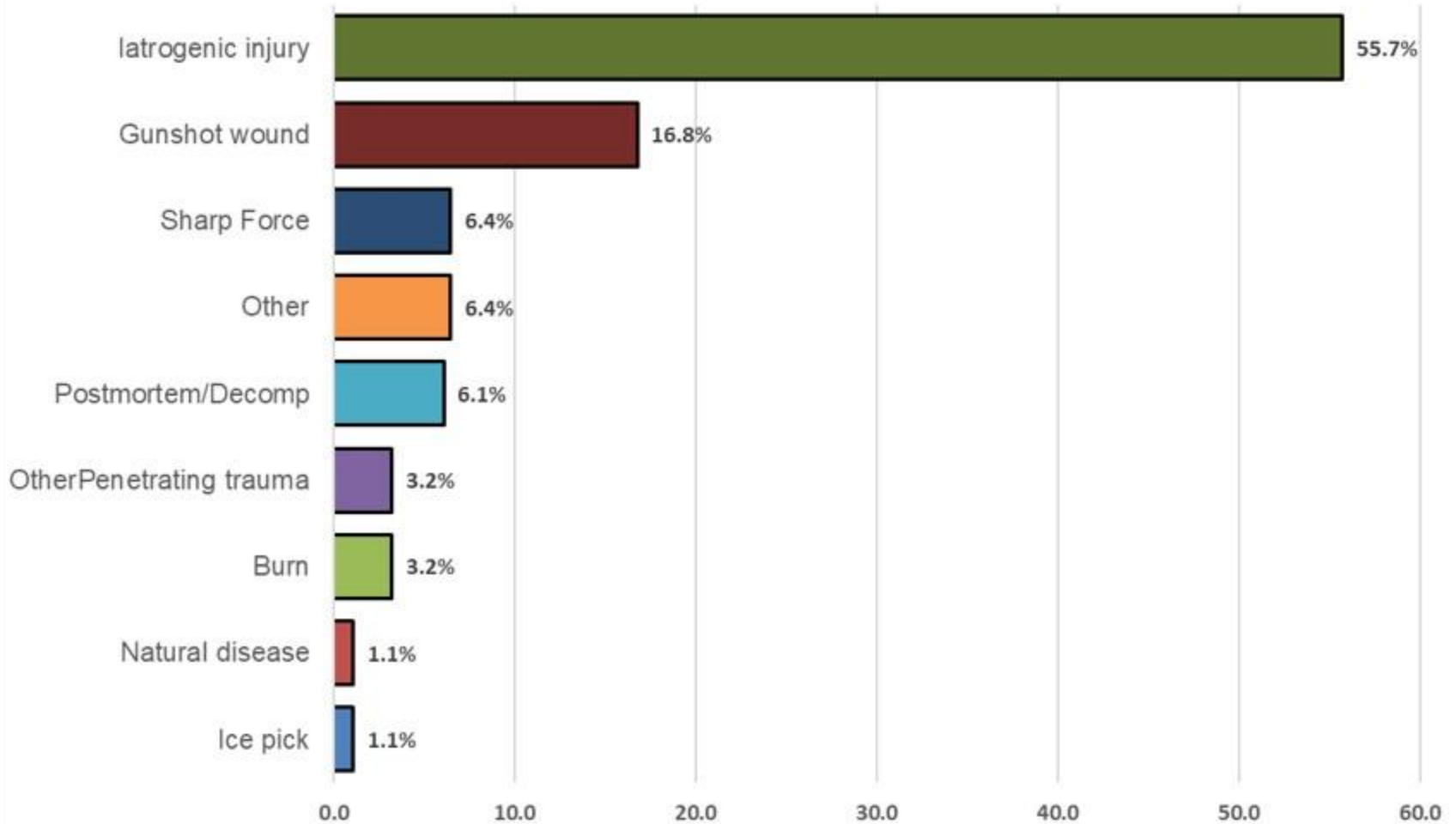
Correct answer:

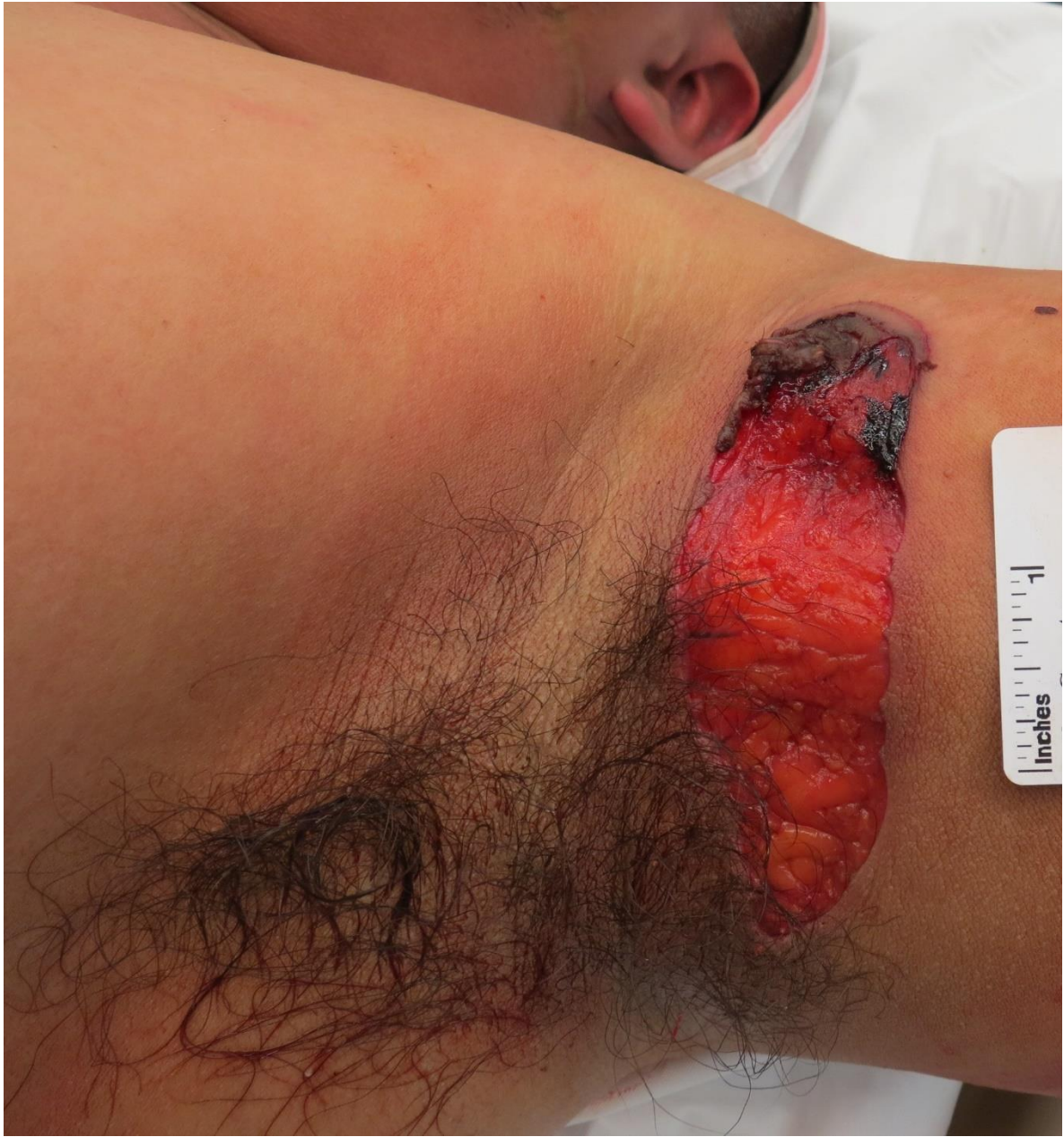The decedent sustained a single gunshot wound of the torso. The entrance wound can be seen in Image 1 just below the thoracotomy incision on the left side of the chest. In the axilla is a cut from scissors. The cut was made by the Trauma Team when they cut the decedent's clothing from his body. We occasionally see these iatrogenic injuries in the axillary regions and on the lateral aspects of the torso on the skin above the iliac crests.

Word Cloud

Gun shot wound spreader Surgical retractor caused wound incision
Iatrogenic injury Post-mortem exit Ice pick GSW entrance wound
Surgical surgical clip medical intervention chest
Gunshot wound device thoracotomy clamp
injury post mortem Rib spreader skin slippage
retractor stab wound artifact due gunshot medical
postmortem used skin Therapeutic intervention iatrogenic
Shored exit Rib Artefact chest spreader Electrocution Bullet knife
rib-spreaders stab used thoracotomy

Answer Distribution





Example of a retractor (rib spreader) injury.

Reference:

Dolinak, D., Matshes, E., & Lew, E. (2005). Forensic Pathology: Principles and Practice. Elsevier. **Chapter 6 describes many sharp force injuries, including those made with scissors!