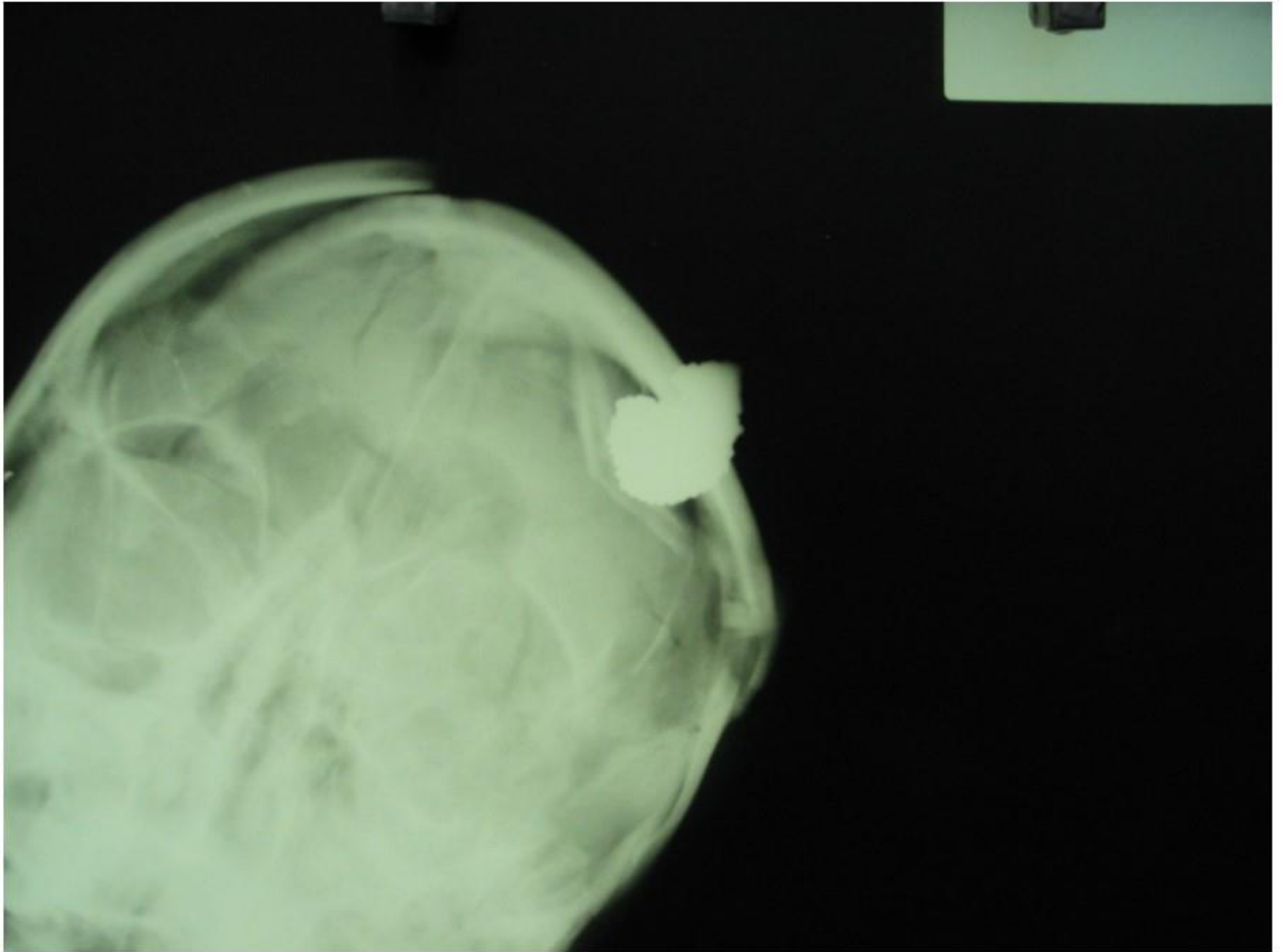




Case #5

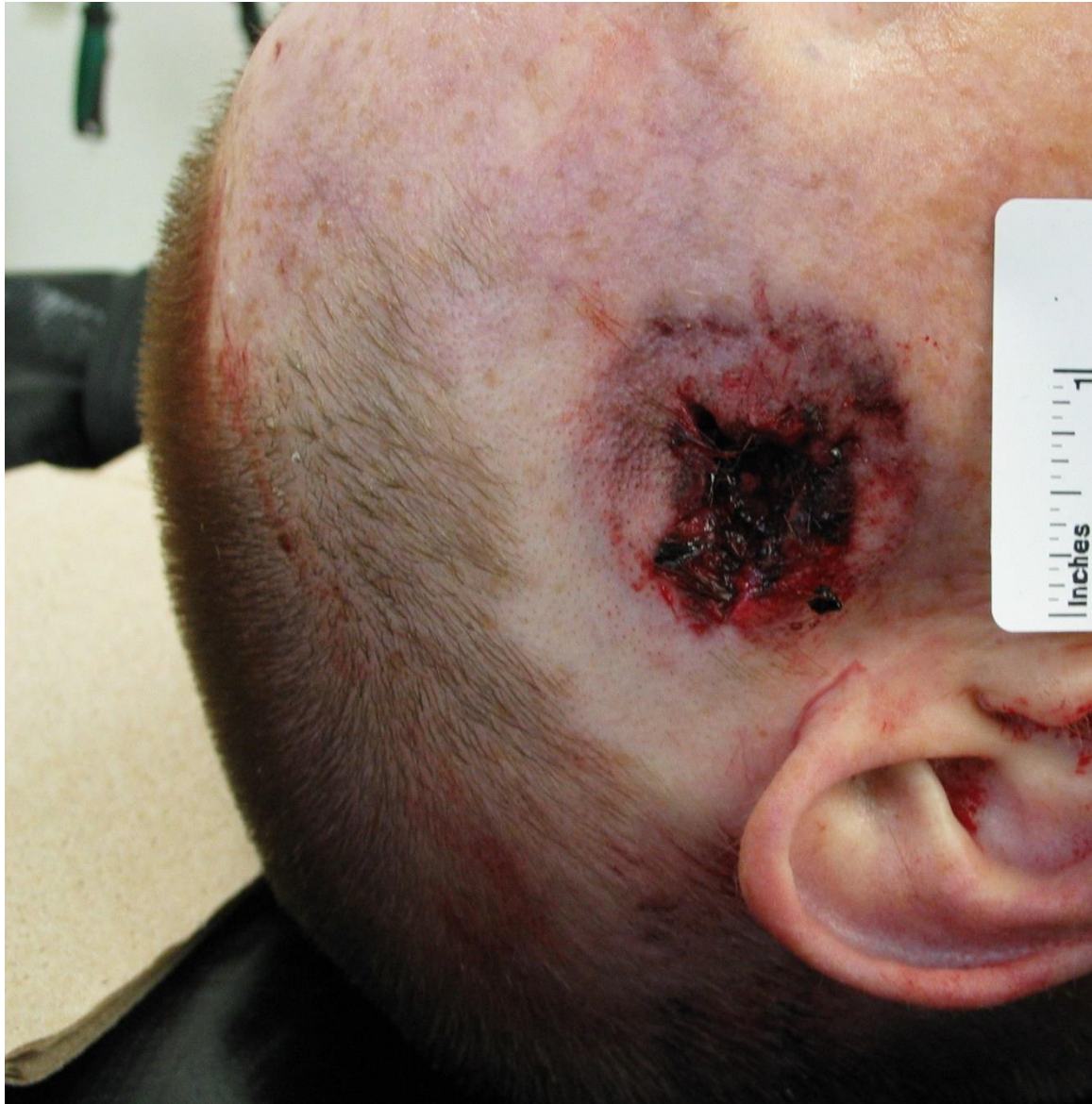NAME Educational Activities Committee

Photo courtesy of Reade Quinton, MD

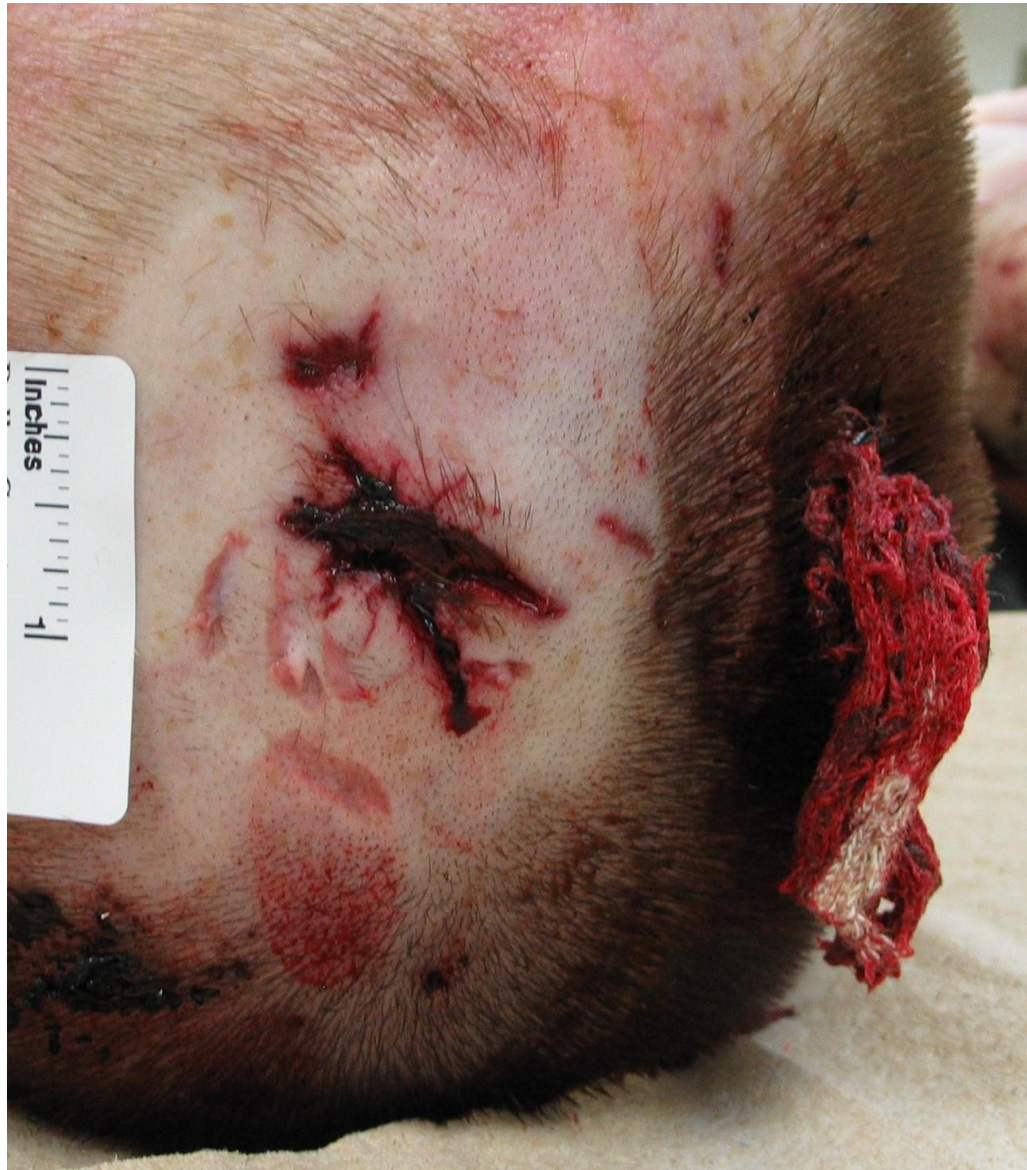

1. This image is from a decedent sitting in his vehicle during a police stand-off. As the officers surrounded the vehicle, they heard a gunshot. Several officers subsequently fired their weapons at/into the vehicle. The radiographic finding shown above is most consistent with:

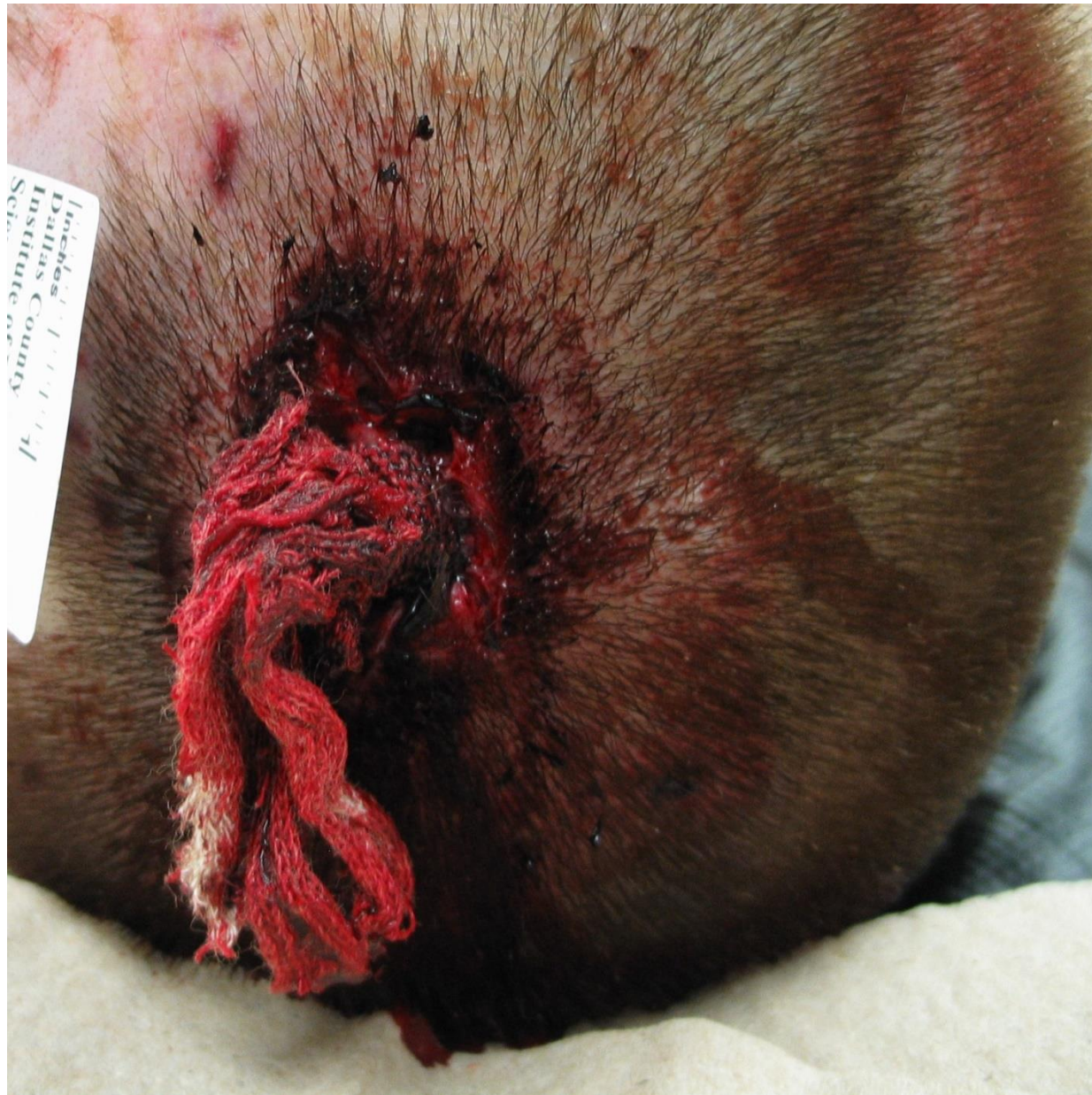- Shotgun slug
- "Less-lethal" shotgun ammunition
- Secondary projectile from interposed target (vehicle)
- Overlying clothing or jewelry
- Birdshot, close range



Contact entrance wound



Exit wound and beanbag round



Beanbag entrance



Beanbag round

In this particular case, as officers surrounded the suspect's vehicle, he shot himself in the head (see entrance and exit images attached). Hearing the gunshot, one officer accidentally fired his shotgun, which contained bean bag rounds. The round struck the suspect's head just above the handgun exit defect.

Responses:

A. Shotgun slug (10.98% responses)

Classic shotgun slugs are single, rounded soft lead projectiles with a deeply concave base (see Di Maio, Gunshot Wounds). When they enter the body, they tend to flatten, and will often break into comma or C-shaped fragments on X-ray. The image in our case represents a much larger projectile that is composed of tightly arranged birdshot, as observed at the scalloped margins of the projectile.

B. "Less-lethal" shotgun ammunition (Correct answer, 45.66% of responses)

Non-lethal or "less-lethal" ammunition is often employed in crowd dispersal or riot control. These types of ammunition can include rubber or wax bullets, sponge "grenades", airfoil projectiles, and bean bag rounds among others. Bean bag rounds (also known as "flexible baton" rounds) consist of a fabric bag containing birdshot (see attached images). Though designed to not penetrate the skin, these rounds have been documented to penetrate skin, scalp, and even skull. However, even without penetration, beanbag round strikes to the head or trunk can cause serious bodily injury and even death. In this particular case, one could argue that the fractures created by the decedent's handgun may have made penetration of the bean bag round easier. A recent publication (see below) shows the exact same injuries in several victims without pre-existing head trauma at a recent protest.

C. Secondary projectile from interposed target (vehicle) (30.64% responses)

Secondary projectiles from the vehicle are likely in a case like this, where it is very possible that a firearm projectile will strike the vehicle. However, the shape of this object is not as irregular as one would expect from a broken-off fragment of the vehicle.

D. Overlying clothing or jewelry (10.98% responses)

One should always keep in mind clothing and jewelry when imaging a firearm victim. In this particular case, the decedent was not wearing a hat and had nothing else in his hair. Of note, some of the fractures of the calvarium also seem to conform to the shape of the object, suggesting that it is truly penetrating the skull.

E. Birdshot, close range (1.73% responses)

While in a manner of speaking, this does in fact represent birdshot, it is packed within a fabric bag. Thus all of the shot is tightly collected in one location. In a classic close range shotgun (birdshot) injury, one may see multiple birdshot scattered throughout the brain and calvarium. More likely, most if not all of the birdshot would exit the head at that range.

References:

Olson KA, Haselden LE, Zaunbrecher RA, et al. Penetrating Injuries from “Less Lethal” Beanbag Munitions. *New England Journal of Medicine*. Correspondence, Aug 14, 2020 DOI: 10.1056/NEJMc2025923

de Brito D, Challoner KR, Sehgal A, Mallon W. The injury pattern of a new law enforcement weapon: the police bean bag. *Ann Emerg Med* 2001; 38: 383-90.

Di Maio JM. Wounds from Shotguns: Miscellaneous Shotgun Ammunition. In: *Gunshot Wounds*. Boca Raton, FL: CRC Press; 1999