

# Tackling the Challenges of Fetal Autopsies in the Setting of Maternal Trauma

---

BY DR. DAGGETT, DR. ATHERTON, DR. DYE, DR. MCCLESKEY



## Financial Disclosures

---

I have no financial disclosures to announce




# Case 1

---

14 week stillborn fetus

Mother was shot in the LUQ of the abdomen

Fetal heart tones noted in ED prior to surgery



# Autopsy findings

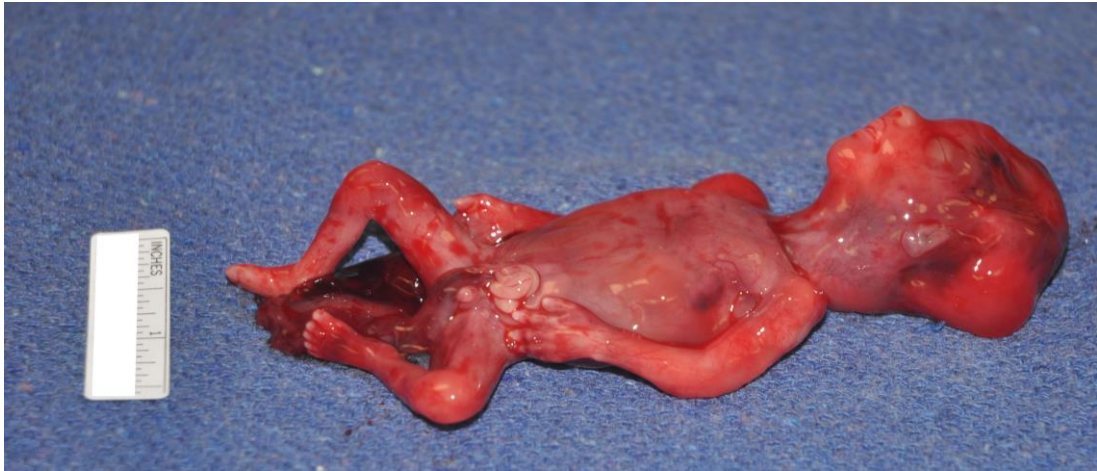---

Stillborn fetus consistent with 14 wks gestation

Gastroschisis identified

Fetus and uterus not struck by the bullet based on ultrasound performed in the ER





## Cause of Death

---

Intrauterine fetal demise following maternal trauma

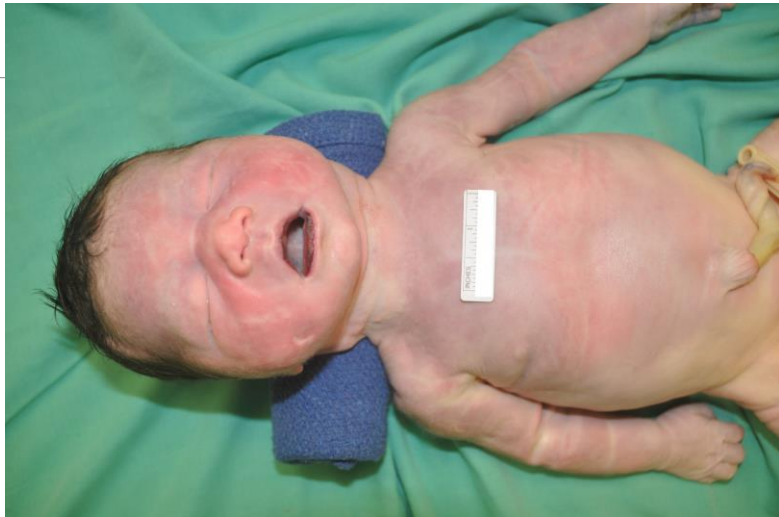- No physical findings to contribute to cause of death
- Cause of death determined by maternal history
- Gastroschisis noncontributory to cause of death

## Case 2

---

36 week gestational age male fetus

Maternal history of drug abuse



# Autopsy findings

---

## Petechial hemorrhages

- Thymus
- Lungs

## Placenta

- Acute hemorrhage at the edge of the placental disk
- 


# Toxicology

---

## Meconium

- Morphine 153 ng/g
- Codeine 33ng/g

## Samples taken

- Blood: ascending aorta, pulmonary trunk
  - Other fluids: urine, vitreous humor, bile
- 

# Fetal metabolism of morphine

---

Metabolized by glucuronidation

Drugs begin accumulating in meconium around 12 weeks of gestation

Metabolized by liver and kidneys

- Bile excreted into the meconium
- Excreted urine swallowed to begin accumulating in meconium



# Meconium drug testing

---

Effective sample for drug screening for:

- Amphetamines
- Opiates
- Cocaine
- Cannabinoids

## Case 3

---

Male fetus 26 weeks gestational age

Delivered by caesarean section

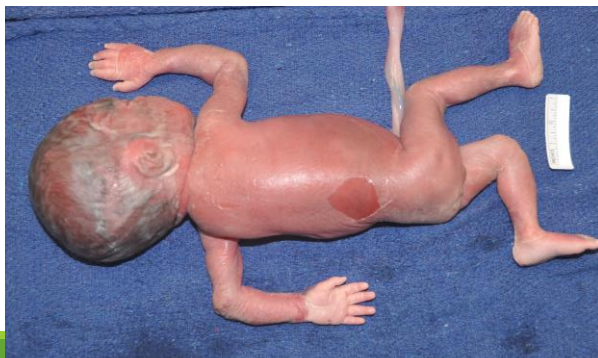Report of mother being assaulted 1 day prior to delivery

## External examination

---

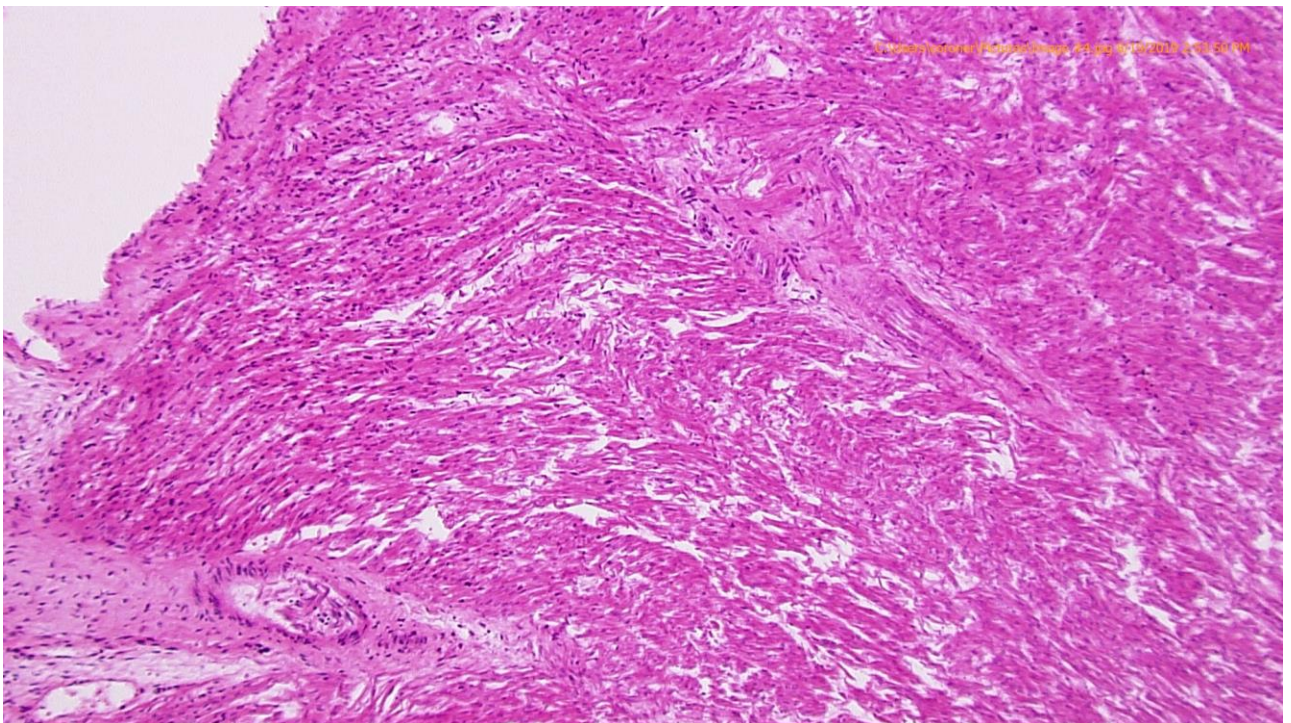
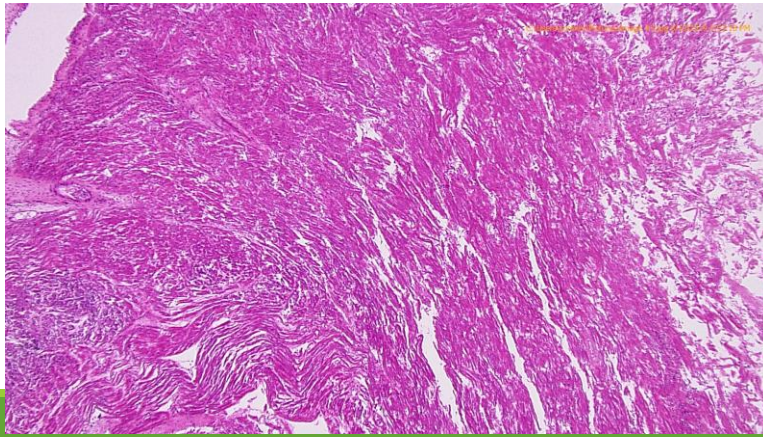
Maceration of ~5% of the body surface

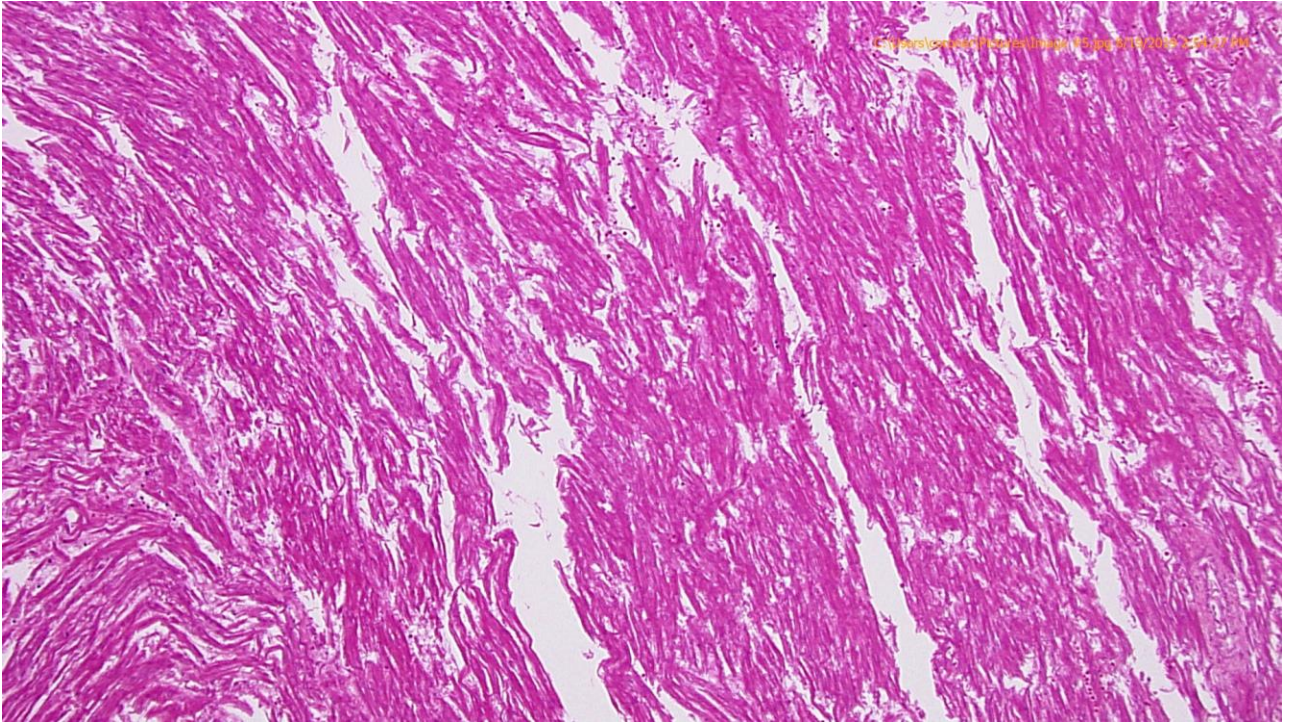
Red-brown discoloration of the umbilical cord



## Internal examination

- Bilateral pleural petechia
- Loss nuclear basophilia of the inner half of the myocardium

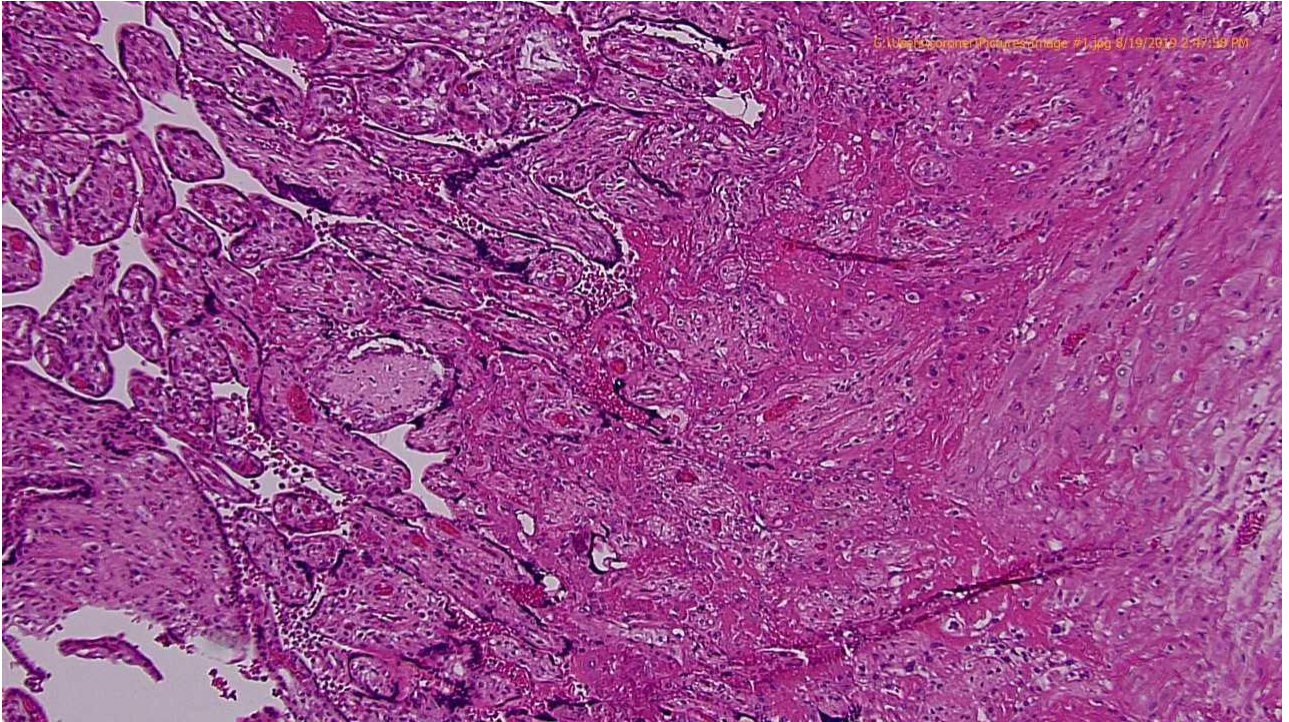




## Placenta examination

---

- Necrotic villi
- Intervillous fibrinoid change
- Mildly increased nucleated red blood cells
- Focal intervillous hemorrhage



## Intrauterine retention times


Placental Histology	Post-Demise Interval	Sensitivity	Specificity	PPV
Intravascular karyorrhexis in small villous vessels of several different regions	≥ 6 hrs	94%	100%	1.0
Multifocal (10-25%) vessel luminal abnormalities	≥ 48 hrs	94%	100%	1.0
Extensive (>25%) vessel luminal abnormalities	≥ 2 wks	78%	98%	0.875
Extensive (>25%) avascular villi	≥ 2 wks	100%	93%	0.75

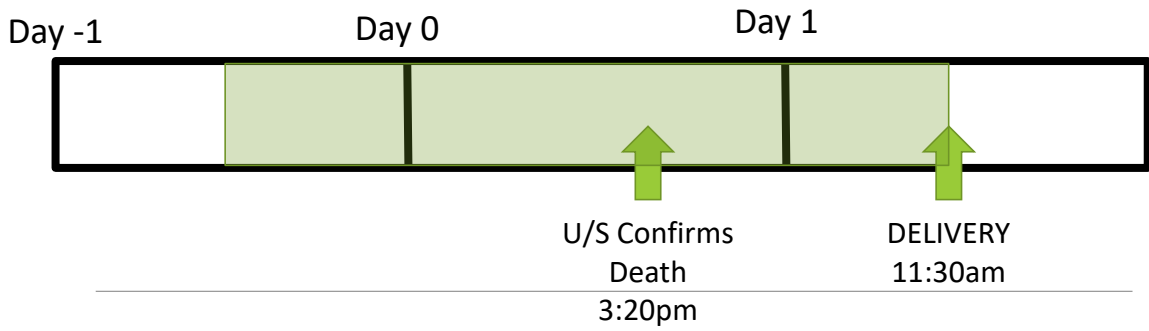
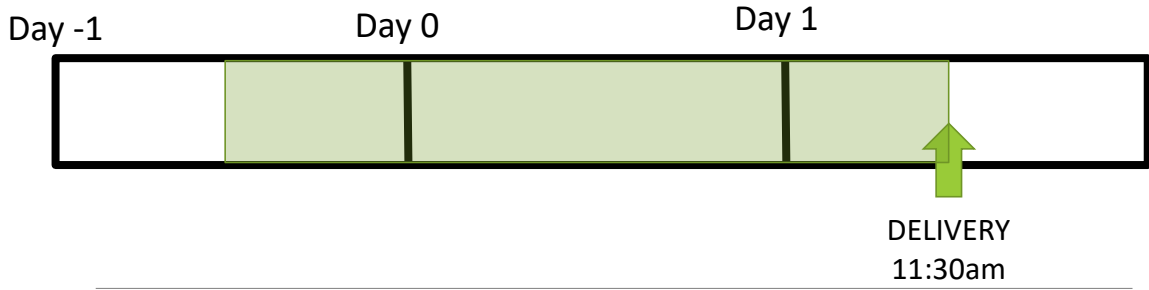
## Intrauterine retention times

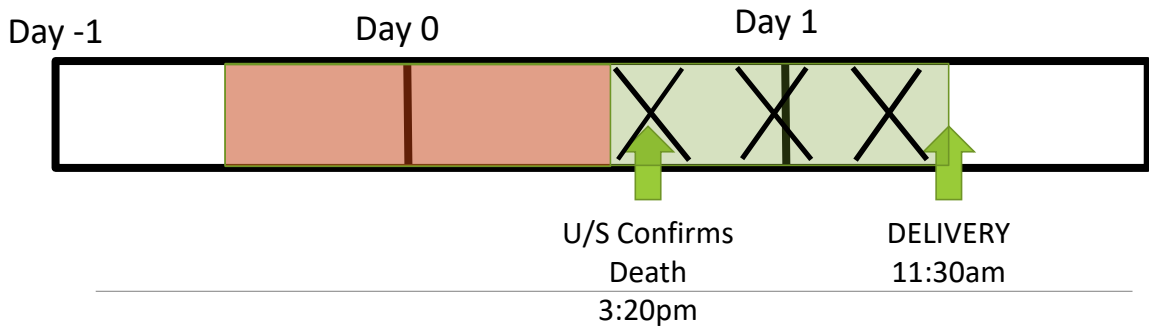
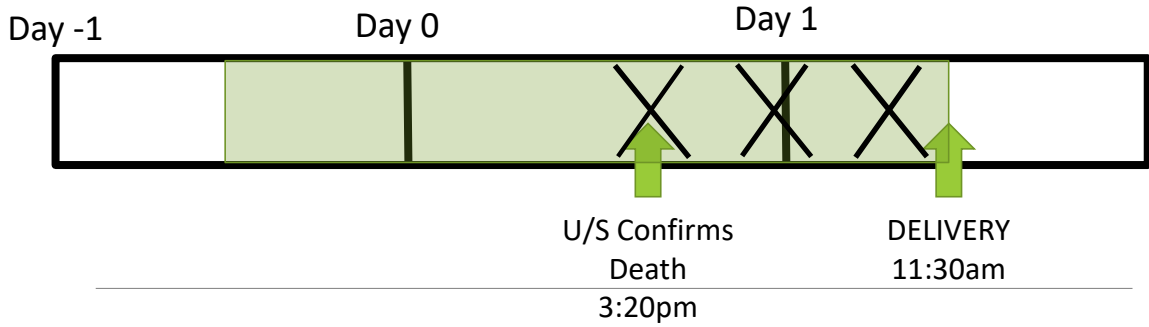
External Fetal Examination	Post Demise Interval	Sensitivity	Specificity	PPV
Desquamation <1 cm	≥ 6hrs	86%	100%	1.0
Desquamation of face, back, or abdomen	≥ 12hrs	80%	100%	1.0
Desquamation of ≥ 5% of body surface	≥18hrs	80%	100%	1.0
Desquamation ≥ 2 of 11 body zones	≥18hrs	90%	92%	0.9
Mummification	≥2 weeks	100%	100%	1.0

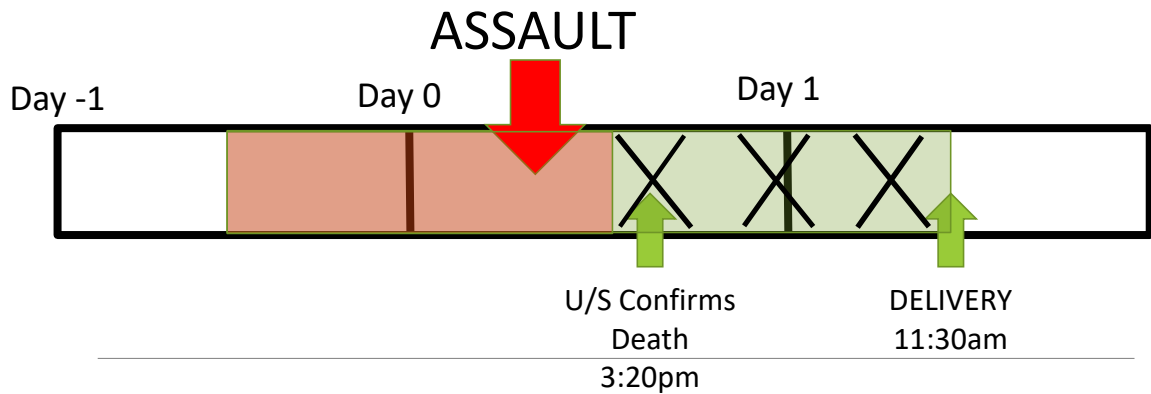
## Intrauterine retention times

External Fetal Examination	Post Demise Interval	Sensitivity	Specificity	PPV
Kidney: Loss of tubular nuclear basophilia	≥ 4 hrs	97%	89%	0.97
Liver: Loss of hepatocyte nuclear basophilia	≥ 24 hrs	100%	92%	0.89
Myocardium: Inner ½ loss of nuclear basophilia	≥ 24 hrs	94%	100%	1.0
Myocardium: Outer ½ loss of nuclear basophilia	≥ 48 hrs	100%	96%	0.91
Bronchus: Loss of epithelial nuclear basophilia ≥ 1% of cells	≥ 96hrs	100%	97%	0.91
Liver: Loss of nuclear basophilia 100% of cells	≥ 96hrs	91%	100%	1.0
GI tract: Loss of nuclear basophilia 100% of cells	≥ 1 week	90%	100%	1.0
Adrenal: Loss of nuclear basophilia 100% of cells	≥1 week	100%	100%	1.0
Trachea: Loss of chondrocyte nuclear basophilia ≥1% of cells	≥1 week	89%	100%	1.0
Kidney: loss of nuclear basophilia 100%	≥4 weeks	100%	98%	0.88









## Work Cited

Montgomery D, Plate C, Alder SC, Jones M, Jones J and Christensen. *Testing for Fetal Exposure to Illicit Drugs Using Umbilical Cord Tissue vs Meconium*. **Journal of Perinatology** (2006) 26, 11-14.

Gareri J, Klein J, and Koren G. *Drugs of Abuse Testing in Meconium*. **Clinica Chimica Acta** (2006) 101-111.

Coles R, Kushnir M, Nelson G, McMillin G and Urry F. *Simultaneous Determination of Codeine, Morphine, Hydrocodone, Hydromorphone, Oxycodone, and 6-Acetylmorphine in Urine, Serum, Plasma, Whole Blood, and Meconium by LC-MS-MS*. **Journal of Analytical Toxicology** (2007) 31, 1-14.

Genest Dr et al. *Estimating the Time of Death in Stillborn Fetuses: 1. Histologic Evaluation of Fetal Organs ; an Autopsy Study of 150 Stillborns*. **Obstet Gynecol** (1992) 80, 572-84.